



The impact of cantilever direction on the clinical outcome of implant-supported fixed dental prostheses

By

Hayat Taresh Obaid Alaleeli

DDS, Ajman University of Science and Technology, 2009

Principal Supervisor:

Associate Professor Moosa Abu Zayda

Co-supervisor:

Professor Alexander Milosevic

Presented to the Hamdan Bin Mohamed College of Dental Medicine of Mohammed Bin Rashid University of Medicine and Health Science in Partial Fulfillment of the Requirements for the Degree of Master of Science in Prosthodontics 2017

ABSTRACT

The impact of cantilever direction on the clinical outcome of implant-supported fixed dental prostheses

Hayat Taresh Obaid Alaleeli

Supervisors: Dr. Moosa Abu Zayda

Professor Alexander Milosevic

It has been shown that dental implants tend to lose bone over time, which ultimately results in soft tissue loss. Recent studies, however, suggest that the design of implant-supported prostheses may contribute to peri-implant tissue stability.

Aim: To evaluate retrospectively radiographic bone loss around implants supporting cantilevered pontics with either mesial or distal direction, and to identify the technical complications that may occur with mesial/distal cantilever fixed dental prosthesis.

Material and Methods: Records of 14 partially dentate patients, aged between 45-83 years (mean age 69.4), who were treated from March 2003 to March 2015, with mesial/distal cantilever implant-supported fixed dental prostheses were reviewed. For each implant, the radiographs from the time of implant loading were compared to radiographs from the last follow-up visit.

There were evaluated regarding:

- 1- The distance from widest diameter of the abutment to the crest of the peri-implant bone.
- 2- The radiographic changes of marginal hard tissue height from the time of implant loading compared to the time of the last follow-up appointment.

Technical complications were noted as (screw-loosening, prosthesis de-cementation and prosthesis loosening).

Results: A total of 28 cantilever implant-supported fixed dental prostheses supporting 32 cantilever units were evaluated. Of these 10 (35.7%) had mesial cantilevers, while 18 (64.7%) had a distal cantilever. There was no significant difference in the distribution of the cases between males and females (7 males and 7 females). The non-smokers were 43%. And the non-recorded were 29%. All technical complications associated with implants adjacent to distal cantilever pontics (prosthesis loosening $P= 0.114$, prosthesis de-cementation $P= 0.114$ and implant abutment screw-loosening: $P= 0.37$). Furthermore, all technical complications occurred with cantilever arm length < 10 mm. Mesial and distal bone loss on implants adjacent to the cantilevered units was not state different if cantilever direction was mesial or distal (mesial cantilever $P= 0.533$, distal cantilever: $P= 0.82$)

Conclusion: Within the limitation of this study, marginal bone loss does not seem to be influenced by the presence of mesial or distal cantilever extensions. Minor technical complications were found with a distal cantilever (prosthesis loosening, prosthesis decementation and implant abutment screw-loosening).

DEDICATION

I would like to dedicate this thesis to my mum, my husband and to my brothers and sisters. Their boundless love and guidance have encouraged me to accomplish all my professional and personal goals.

DECLARATION

I declare that all the content of the thesis is my own work. There is no conflict of interest with any other entity or organization.

Name: Hayat Taresh Alaleeli

Signature:

ACKNOWLEDGMENTS

To the Staff of MBRU Graduate Prosthodontics for their help during my residency

To the Faculty at MBRU Prosthodontic Program, for their guidance, help, patience and teachings

My special acknowledgement goes to Associate Professor Moosa Abu Zayda and Associate Professor Ammar Hassan, Professor Alexander Milosevic for sharing with me their experience, knowledge and skills.

To my classmates Fahad, Asma, Noora & Nadia you made residency fun, motivating, and intellectually enriching.

To my precious husband, thank you for all your love and support over the years. Without you, none of my endeavors would have any meaning.

To my son, Hamad for all the fun and joy that he bring to our family

To my mum, brothers and sisters, thank you for your support and taking care of my baby.

TABLE OF CONTENTS	PAGE
ABSTRACT	2
DEDICATION.....	5
DECLARATION.....	6
ACKNOWLEDGMENTS	7
LIST OF FIGURES	
PAGE.....	10

LIST OF TABLES:	PAGE
Table 1: Tooth Vs. Implant.....	13
Table 2: Descriptive variables in the study.....	26
Table 3: Distribution of implant-supported cantilever prosthesis according to their position in the jaw.....	27
Table 4: Technical complications of bridges.....	29
Table 5: Technical complications of implant.....	30
Table 6: Comparison of implant screw-loosening between mesial and distal abutments on bridges according to whether 2 units or > 2 units fixed dental prostheses and cantilever Direction.....	31
Table 7: Comparison of prosthesis de-cementation between mesial and distal cantilever prostheses.....	31
Table 8: Comparison of prosthesis loosening between mesial and distal cantilever prostheses.....	32
Table 9: Marginal bone height from time of cantilever prostheses loading to the last recall visit.....	36
Table 10: Bone Loss Around Implants Supporting Distal Cantilever.....	37
Table 11: Bone Loss Around implants Supporting Mesial Cantilever.....	37
Table 12: Comparison of marginal bone loss between mesial and distal cantilevers on mesial and distal sides of implant supporting cantilever unit(s).....	38

LIST OF FIGURES	PAGE
Figure 1: Annual failure rates of implant supporting FDPs after 5 years.....	3
Figure 2: External and Internal hex abutment.....	4
Figure 3: Radiograph of cFDP showing measurement landmarks (BL: bone loss,CL: cantilever length).....	23
Figure 4: Smoking status.....	27
Figure 5: Technical complication in relation to implant/cantilever number.....	33
Figure 6: Radiographs shows single implant supporting double cantilever pontics (left), single implant supporting single cantilever pontic (middle) and image of double implants supporting single cantilever pontic (right).....	34

LIST OF APPENDIX:**PAGE**

Ethical approval letter from DHA.....	61
--	-----------

1. Introduction:

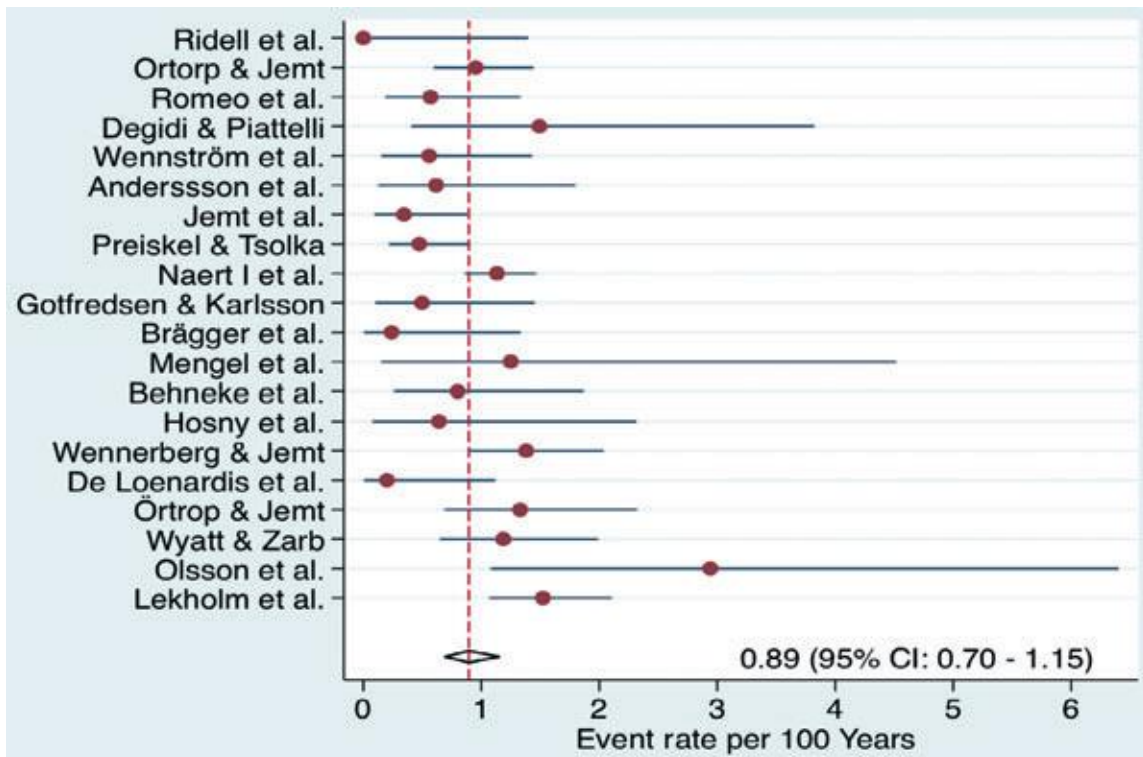
Today, partially edentulous individuals represent the main and steadily increasing group of patients being considered for the rehabilitation with oral implants¹. Most of these patients are middle-aged, that is, between 40 and 50 years when provided with oral implants². Thus, with increasing life expectancy, it is assumable that the patients will be in need of their implant-supported reconstructions to function for decades³. When advising the patient on different treatment options, survival rates and the incidence of biological and technical events should thus base on mean observation periods of at least 5 years to supply the patient with reliable information⁴. Furthermore, the treatment decision should ideally be based on systematic reviews of the available evidence⁵. It may be stated that implant-supported fixed dental prostheses (FDPs) are a safe and predictable treatment method with high survival rates. However, biological and technical complications are frequent. This, in turn, means that substantial amount of chair time has to be accepted by the patient and the dental service following the incorporation of implant-supported FDPs⁵.

To minimize the time needed to address complications, dental professionals should make great efforts in choosing reliable components and materials for implant-supported FDPs and the patients should be part of a well-structured maintenance program after treatment with implant-supported FDPs. Biological complications for implant-supported restorations should be defined by (1) the threshold level of pocket probing depth (PPD), (2) the presence/absence of bleeding on probing (BOP)/suppuration assessed at any examination interval, and (3) marginal bone loss over time in relation to the bone level assessed at the time of prosthesis installation. Technical complications should be divided into (1) major, such as implant fracture, abutment fracture, and loss of supra-structures, (2) medium, such as abutment fracture, veneer or framework fractures, and phonetic complications, and (3) minor, such as abutment and screw loosening, loss of retention, de-bonding, loss of screw hole sealing, veneer chipping (to be polished), and occlusal adjustments. Esthetic impairments should be reported⁶. *Biologic complications* refer to disturbances in implant function that affect the supporting peri-implant tissues. These include early and late implant failures and adverse reactions in the peri-implant hard and soft tissues. *Technical complications* are collective term for mechanical damages of the implant, implant components, and suprastructures⁷.

Several reports have been published, showing favorable long-term outcomes with different implant systems⁸. The term “long term” has been defined as a follow-up of at least 5 years². Traditionally, life table analyses and Kaplan–Meier statistics have been applied in implant survival studies. Often patient cohorts were analyzed prospectively or retrospectively with periods up to a certain observation time. As an example, a long-term evaluation of non-submerged ITI implants reported an 8-year life table analysis in which

the mean follow-up time was 3.1 years for individual observation periods that ranged from 1 to 8 years². The term “Survival” was defined as FDP remaining in-situ with or without modifications. “Success” was defined as the FDPs remaining in- situ free of all complications over the entire observation period. Even with follow-up periods of at least 5 years, some clinicians may argue that this is still too short to obtain reliable information on survival and complication rates⁹. Due to the fact that the use of dental implants for rehabilitation of partially edentulous patients is relatively new, a mean follow-up period of at least 5 years was a necessary compromise. The majority of older longitudinal studies on dental implants concentrated on implants survival and did not address the reconstructions at all. Nor did they distinguish between Different types of reconstructions such as implant-supported FDPs, implant-supported single crowns, implant-supported fixed complete dentures, combined tooth-implant-supported FDPs, or implant-supported overdentures (Figure 1)³.

Figure 1: Annual failure rates of implant supporting FDPs after 5 years



2. Literature Review:

2.1. History of Dental Implants

Dental implants are fabricated in a style that mimics the tooth root shape and form as alternate for lost tooth. In the beginning, dental implants were made of commercially pure titanium and made as a screw-in configuration that contained a smooth surface in between the threads¹⁰. Dr. Per-Ingvar Branemark, discovered that a titanium dental implant could establish a direct host bone-to-implant connection, a phenomenon known as “osseointegration”¹¹. Osteointegration describes direct structural and functional connection between living bone and the surface of the dental implant. Normally the implant is connected to the abutment via an external/internal hex (figure 2). Particularly external hex abutment implant has had documentation for more than 30 original implant design^{12,13}.

Figure 2: External and Internal hex abutment

At the time, within the first year after implant placement the (accepted bone loss) was 1-1.5 mm, followed by 0.2 mm annually using external hex abutment implant system. Despite the long-term documentation of external hex abutment



type of implant, some major problems were recorded, mainly that there was a continuous bone loss over time^{12, 13}. From aesthetic point of view, bone loss becomes an important issue when related to aesthetic zones that are mainly visible during smiling. Once bone loss occurs the superimposing soft tissue will follow the bone, which will result in an unsatisfactory aesthetic complication¹⁴. Other complications that were detected in this implant system include screw loosening and/or fracture¹⁵. An external hex configuration, displayed a hex on top of the implant to which the abutment could be connected. Thus, there have been some design modifications to the root form dental implant in order to overcome the existing limitations. These modified designs of implant aspects included the replacement of an external hex connection with an internal hex connection, as well as the roughening of the implant surface. The roughened surface was thought to increase the contact surface area of implant-to-bone in comparison to the smooth surface implant. Furthermore, this design promoted better mechanical stability following placement, better retention of the blood clot, and finally, greater stimulation of the bone healing^{15,16}. The internal hex connection was created to reduce the number of prosthetic complications that were experienced with the external hex system¹⁴. Recent designs of dental implants have overcome some of the inherent problems that were experienced with the smooth surface implant by incorporating a roughened surface, as well as an internal hex abutment connection design. Long-term studies supporting the original smooth surface implants are lacking¹⁷.

As stated earlier dental implants are widely used to restore missing teeth as well as to serve as abutments for fixed dental prostheses, removable dental prostheses and complete

dentures. In the U.S the most common causes of the loss of at least one permanent tooth are trauma, periodontitis, failed endodontics, or tooth decay and this was reported in 69% of people between ages 35 to 44 years. As a result, by age 74, 26% of adults have lost all of their permanent teeth¹⁸. In 2008, the global dental implant market increased to \$3.4 billion dollars, while the market for traditional crowns and bridges decreased to \$4.4 billion dollars. The market value of dental implants is anticipated to reach \$8.1 billion by 2015¹⁸.

2.2. Major Clinical Challenges for Dental Implants

Dental implants require sufficient alveolar bone, both in width and in height, to acquire adequate primary stability, and to eventually exert its support function. In some cases such as severely atrophic edentulous mandibles and thin maxillary ridges near to the sinus floor, implant treatment is not an option without bone augmentation. In addition, bone loss also results in esthetic problems in the anterior maxilla¹⁹. On the other hand, patients with implant placement should wait 3 to 6 months for successful osseointegration and final permanent restoration. Therefore, methods to augment alveolar bone and shorten the waiting time are two major clinical challenges for dental implantology.

2.3. Rationale for Dental Implant Application

Dental implants have many advantages over conventional crowns, fixed dental prostheses and removable dental prostheses. Dental implants are able to preserve adjacent tooth structure because abutment tooth preparation is not required as in single crowns and FDPs. The risk of recurrent caries in dental implants is not considered, while caries is considered to be the most frequent reason for failure of existing restorations such as onlays, crowns, and bridges²⁰. Implants can provide much more stability and retention of implant-supported prostheses than traditional tooth/tissue-borne partial dentures and tissue borne complete dentures²¹. In addition, the most important aspect of dental implants is to preserve alveolar bone. It has been reported that marginal peri-implant bone loss over a 10-year observation period was less than 1 mm for both mandible and maxillae¹⁸. Because of alveolar bone preservation, dental implants can be used to restore and maintain the gingival tissue emergence profile in the maxillary esthetic zone after anterior tooth extraction²². Furthermore, the preservation of alveolar bone implants may be a key rationale for its 90% long-term survival rate²². However, Schoppa et al (2003)²³ reported the loss of alveolar bone 1 year following tooth extraction to be 6 mm in width and 1.2mm in height.

2.4. Osteointegration

Dental implantology, is currently the most intensively developing field of dentistry. The success, survival and long-term prognosis of implant prosthetic therapy depend primarily on the anchorage of the implant to the jawbone, *i.e.* on **osseointegration**.

In the 1960s, Brånemark *et al.*¹¹ stumbled upon the phenomenon of osteointegration when using titanium (Ti) in animal models, with little idea of the impact this discovery

would have on the rehabilitation of future medical and dental patients. “Osseointegration”, was characterized by a number of clinical and ultra-structural observations. Osseointegration may broadly be defined as the dynamic interaction and direct contact of living bone with a biocompatible implant in the absence of an interposing soft tissue layer²⁴⁻²⁶.

Although the clinical term osseointegration describes the anchorage of endosseous implants to withstand functional loading, it provides no insight into the mechanisms of bony healing around such implants. However, in the last decade it has become clear that the long-term success of dental implants also depends on the complex bio-integration of these alloplastic materials, which is determined by the responses of the surrounding host tissues (the alveolar bone, the conjunctival part of the oral soft tissues and the gingival epithelium). Nevertheless, an understanding of the sequence of bone healing events around endosseous implants is believed to be critical in developing biologic design criteria for implant surfaces. Bone growth on the implant surface can be phenomenologically subdivided into three distinct phases that can be addressed experimentally²⁷. The first, *osteoconduction*, relies on the migration of differentiating osteogenic cells to the implant surface, through a temporary connective tissue scaffold. Anchorage of this scaffold to the implant surface is a function of the implant surface design. The second, *de novo bone formation*, results in a mineralized interfacial matrix, equivalent to that seen in cement lines in natural bone tissue, being laid down on the implant surface. The implant surface topography determines whether the interfacial bone formed is bonded to the implant. A third tissue response, *bone remodelling*, creates a bone-implant interface comprising *de novo* bone formation. Treatment outcomes in

dental implantology depend critically on the implant surface designs that optimize the biological response during each of these three distinct integration phases²⁸.

Today, much effort is devoted to the design; synthesis and fabrication of Ti dental implants in order to achieve long term secure anchoring in the bone. Basically, this means the ability of implants to carry and sustain the dynamic and static loads that they are subjected to. The bulk structure of the material governs this ability. Evidently, it is important to obtain adequate function in the shortest possible healing time, with a very small failure rate and with minimal discomfort for the patient. These factors are also important for cost reasons. A wide variety of materials have been used to produce endosseous implants^{28, 29}.

2.5. Implant materials:

Currently, Ti and its alloys are the most commonly utilized dental and orthopedic implant materials that meet the most important requirements^{30,31}. The properties of Ti and its surface, which is covered by a native oxide layer, are appropriate to allow its use as a biocompatible material³⁰. At a cellular level, the relationship of an implant with the surrounding tissue is highly dependent on the interaction between the passive titanium oxide (TiO₂), which is formed on the surface of a Ti implant, and biological elements such as collagen, osteoblasts, fibroblasts and blood constituents^{22,31}. The TiO₂ layer is very stable, corrosion-resistant and may be manipulated to have variable thickness.

2.6. Success interface of osteointegration:

The clinician is often faced with the challenge of identifying successful osseointegration

of a dental implant. Clinical success is determined by a lack of mobility and by the ability of the implant to resist functional loading (chewing force) without mechanical deformation and to transfer the load to the alveolar bone without deterioration of the bony interface³². Radiographically, the bone should appear to be closely apposed to the implant surface. The resolution currently achievable in medical imaging, however, is several orders of magnitude less than what is required to observe a soft tissue cell. Accordingly, radiographic assessment alone is unsuitable to determine with certainty whether soft tissue is present³³. A number of studies have analyzed this bone to Ti interface histologically and ultra-structurally, often with inconsistent findings. The difficulty arises primarily with the need to prepare and section the specimens without changing or damaging the interface. Recent studies have utilized CT scanning to obtain a 3-dimensional picture of the implant interface^{34, 35}.

2.7. Implant success and failure criteria:

Marginal bone loss considered as a key criterion of long-term success following dental implants. Since bone-anchored prostheses are constructed in the oral environment for a lifetime, a pathologic decrease of marginal bone could lead to loss of bone anchorage of the implant, and it is important to know what factors causing the bone resorption. In general, reasons for bone loss can be divided into the following categories: The size of the implants, age and gender of patients, and the presence of cantilevers as influencing factors are subject of debate³⁶. Recent studies claimed that smoking was a factor in identifying a subject with progressive bone loss around an implant with 69% accuracy³⁷. In a long-term follow-up of implant treatment, it was concluded that patients who had a

history of periodontal disease and patients that smoked are more likely to develop bone loss around implants³⁸. Patient's ability in performing proper oral hygiene procedures has also been shown to influence bone levels around implants³⁷.

Furthermore, occlusion is a primary factor for implants success in the long run. Thus, occlusal overload can lead to mechanical stresses on both dental implants and implant prostheses. There are a myriad of variables in a patient population, so no one occlusal scheme can fit all implant patients. Thus, if a clinical condition is likely to increase biomechanical stresses, dentists should implement occlusal mechanisms to decrease the stresses and develop an occlusal scheme that minimizes risk factors and allows the restoration to function in harmony with the rest of the stomatognathic system. This is what we call implant-protected occlusion³⁹.

Occlusal overload is often regarded as one of the main causes for peri-implant bone loss and implant prosthesis failure, because it can cause crestal bone loss, thus increasing the anaerobic sulcus depth and peri-implant disease states if patients cannot clean well. So a harmonious occlusal scheme is a primary objective⁴⁰.

2.8. Differences between natural teeth and implants

The basic difference between natural teeth and endosseous dental implants is that the natural tooth has a support design that reduces the force to the surrounding crest of bone compared to the same region around an implant. Natural tooth is suspended by the periodontal ligament (PDL), while an endosseous dental implant is in direct contact with the bone through osseointegration. The PDL absorbs shocks and distributes occlusal

stresses away along the axis of natural teeth. However, an endosseous dental implant connected to the bone by osseointegration lacks those advantages of the PDL⁴¹ (Table 1).

Periodontal tissues are uniquely innervated and structured to retain and support teeth. When natural teeth are lost, both occlusion and attachment with its proprioceptive feedback mechanism are lost. When loaded, the distribution of forces begins with the primary phase of periodontal compliance that is primarily non-linear and complex, followed by the secondary movement phase, which occurs with involvement of the alveolar bone. In contrast, the movement of an implant under loading is dependent on linear and elastic deformation of the bone. The PDL in a natural tooth can produce differences in force adaptation compared with osseointegrated implants due to its shock-absorbing and stress-distributing functions Table 1⁴¹.

Table 1: Natural tooth Vs. Implants

Parameter	Tooth	Implant
Composition	Calcium and phosphorus (hydroxyapatite)	Primarily titanium and titanium based alloys
Nature	Living	Nonliving
Gingival sulcus depth	Shallow	Depends upon abutment length and restoration margin
Junctional epithelium	On enamel	On titanium
Connectivity issue	Perpendicular to tooth surfaces	Parallel and circular fibers; no attachment to implant or bone
Gingival fibers	Complex array inserted into cementum above crestal bone	No organized collagen fiber attachment
Crest of bone	1 to 2 mm apical to cements enamel junction	According to implant design
Nerve supply	Present	Absent
Proprioception	Highly sensitive	No ligament receptors
Physical characteristics	Physiologic mobility caused by viscoelastic properties of the ligament	Rigid connection to bone, as if ankylosed
Adaptive characteristics	Width of ligament can alter to allow more mobility with increased occlusal forces	No adaptive capacity to allow mobility; orthodontic movement impossible
Connection	Cementum, bone, periodontium	Osseointegration, bone functional ankylosis ligament
Junctional epithelium	Lamina lucida and lucida, lamina dense zones	Lamina, lamina densa, and sublamina lucida zones
Connective tissue	Thirteen groups: perpendicular to tooth surfaces Decreased collagen, increased fibroblasts	Two groups: parallel and circular fibers Increased collagen, decreased fibroblasts
Biological width	2.04 to 2.91 mm	3.08 mm
Vascularity	Greater, suprapariosteal and periodontal ligament	Less, periosteal
Probing depth	3 mm in health	2.5 to 5.00 mm
Bleeding on probing	More reliable	Less reliable

Non-vertical forces are potentially harmful to natural teeth, but during function can cause damage to teeth and the PDL. Non-axial or non-vertical forces will lead to primary trauma from occlusion manifest as a widened PDL and hypermobile tooth. Whereas in implants, the non-axial loads involve the crest of the bone, which is usually traumatic to the supporting structures. According to Parfitt⁴², a lateral force on a healthy natural tooth is rapidly dissipated away from the crest of bone toward the apex of the tooth due to the natural tooth rapidly moving 56~108 μm and rotating around the apical 1/3 of the root. On the other hand, movement of an implant occurs gradually, reaching up to about 10~50 μm under a similar lateral force. So greater forces are concentrated on the crest of the surrounding bone of dental implants in the absence of rotation. Under similar lateral

loads, an implant does not pivot as much as a tooth toward the apex, but instead concentrates greater forces at the crest of the surrounding bone. Therefore, if an initial load of equal magnitude and direction is placed on both an implant and natural tooth, the implant must be protected.

2.9. Implant-supported cantilever fixed dental prosthesis:

Implant-supported cantilever prosthesis is the pontic attached to the implant crown. In daily practice, treatment-planning decisions are influenced by many technical and biological factors that increase the challenge of making the final treatment plan. A further consideration is the cost-benefit ratio of implants treatment³. With regard to prosthesis rehabilitation, implant-supported cantilevers provide simpler rehabilitation procedures compared to surgical reconstructive procedures⁴³. The inclusion of a cantilever may be a simpler option in situations where local conditions of the residual edentulous ridge preclude the possibility to place an implant. This is preferable than surgical reconstructive procedures because of long treatment time, high morbidity and increasing cost⁴³. Cantilevers were used to extend implant supported full arch FDPs since the early applications of the Branemark method, with promising long-term results⁴⁵. Since then, the use of cantilevers in full arch, multiple unit or even single unit FDPs has been relatively common in implant reconstructions. In a cohort of periodontally treated and maintained patients at Berne University, implant-supported cantilever FDPs (cFDPs) represented 8.6% of all FDPs and 27.78% of implant-supported FDPs⁴⁵. In other groups, cFDPs represented 6.9%⁴⁶, 12.35%⁴⁷, 20.53%, and 67% of implant-supported FDPs. However, it has been claimed that cantilever extensions increase the risk of flexion

overload and that this in turn may compromise the prognosis of the prosthetic rehabilitation and the survival of the implants⁴⁸. It has been demonstrated longer cantilevers resulted in higher stress at implant sites, thus triggering greater marginal bone loss around implants. Consequently, a higher incidence of biologic and prosthetic complications was expected for this type of rehabilitation, when compared with those without cantilevers. Cantilevers with less-favorable crown/implant ratios can increase the possibility of overloading, possibly resulting in peri-implant bone loss and prosthesis failure⁴⁹. In terms of cantilever length, a clinical study demonstrated that long cantilevers (≥ 15 mm) induced more implant-prostheses failures compared to cantilevers < 15 mm long⁵⁰. Duyck et al⁵¹; also reported that when a biting force was applied to a distal cantilever, the highest axial forces and bending movements were recorded on the distal implants, which were more pronounced in prostheses supported by only 3 implants, compared to prostheses with 5 or 6 implants. The above study indicated that a shorter cantilever length is more favorable for the success of implant-supported prostheses, particularly for prostheses with fewer implants⁵². The occlusal contact position can determine the direction of force, which may result in overloading of supporting implants, especially during parafunction⁵³. Cantilevers can cause screw loosening and/or prosthetic screw or abutment screw breakage and should be eliminated. Therefore, periodic evaluation of occlusion is necessary⁵². Other studies showed equal success rates in cases with or without a cantilever. Thus, the use of cantilevered restorations is controversial and requires clear evidence for their application. Because the use of cantilevered implant restorations could still be a viable treatment option in many instances, their effect on marginal bone loss and the survival rate of the supporting implants and the prosthetic

maintenance should be clarified⁵⁴. Previous studies^{55,56}, reported a high number of technical complications that might be expected in the presence of a cantilever extension. On the contrary, findings from the statistical analysis showed that there were no differences in prosthetic complications between cantilever and non-cantilever prostheses. Previous systematic reviews pointed out the same issue; technical complications are common for either implant or tooth-supported fixed partial prostheses, independently of the presence or absence of cantilevers^{46,56}. Factors such as the type of restoration used or the number of implants supporting the cantilever in the included studies might justify this observation. Additionally, studies have observed the relationship between prosthetic complications, such as implant fracture, and the combination of cantilevers with bruxism, heavy occlusal forces, or this relationship suggests that besides the presence of a cantilever extension, there are other factors that may influence the appearance of prosthetic complications⁵⁷. Further biases that may cause misleading results are that marginal bone loss could be influenced by many factors not limited only to the presence/absence of a cantilever extension. Another confounding factor that might be considered when assessing peri-implant bone loss is the crown-implant ratio⁵⁷. More recently, it have been demonstrated that prosthesis height does not influence the crestal stress concentration, as displayed by no significantly greater marginal bone loss⁵⁸. Thus, assessing contributing factors for marginal bone loss display show limitations because many confounding elements are may be present and thus difficult to assess⁵⁹. In the aesthetic region in particular, the use of single implant cFDP may help resolve compromising situations, when a limited mesio-distal dimension may jeopardize aesthetics⁶⁰. In such cases inter-implant distance of >3 mm is recommended to minimize

crestal bone loss in between implants⁶¹, which achieved papillary height of 3–4 mm at most of the time (Tarnow 2003)⁶². The use of cantilevers, however, has not been without controversy. Some authors have suggested that occlusal forces on cantilevers are amplified by leverage action, which might result in damaging strain. Finite element analysis (FEA) and in vitro studies have shown cantilever FDPs to develop highest stress/strain levels⁶³, which have been shown to increase with cantilever length above 7 mm⁶⁴. This increased strain has been hypothesized to have a detrimental effect not only on the longevity of the FDP but also on the peri-implant bone and osseointegration and some authors have discouraged the use of cantilevers. However, no clear evidence of the impact of cantilevers on bone and peri-implant tissues has been documented in animal studies, in the presence of adequate plaque control⁶⁵. Systematic reviews showed failure rate per 100 cFDP years of 1.18⁶⁶ comparable to non-cantilever FDPs at 1.03⁴ and no evidence for increase marginal bone loss or biological complications⁶⁶. Furthermore, clinical studies have shown little statistical or clinical difference in the biological outcomes in full arch prosthesis with distal cantilevers⁴³ as well as multi-unit FPDs⁶⁸, in medium term follow-up of 4–10 years. With respect to studies involving technical complications, higher complication rate appears to occur in cFDPs⁴⁵, although few authors have shown higher success rate for cFDPs⁵⁷. A study showed that much of this increased technical failure is related to minor screw loosening and veneer fracture⁵⁵. There is lack of reporting of biological complications involving clinical examinations. Some clinical studies showed a trend but lacked statistical power to detect differences in mean marginal bone loss smaller than 1 mm^{57,69} or lacked cases with >5-year follow-up or appropriate analysis for drop out⁶⁸. With respect to technical complications, there is

considerable variability in the outcomes reported⁶⁶, even when published by the same group. Furthermore, the impact of variables such as cantilever dimensions, number of implants, occlusal scheme and dimensions of prosthesis on survival and success rate remain underexplored⁶⁶.

3. Aim:

- (1) To determine if bone height changes are different on mesial and distal surface of implant adjacent to cantilevered crown units.
- (2) To study the impact of cantilever direction on technical outcomes of implant-supported fixed dental prostheses (FDPs) and bone height. .

4. Material and methods:

4.1. Design: Retrospective study:

This study is a retrospective review of the records of 14 partially dentate patients who were restored with dental implants placed by residents, periodontists and prosthodontists working in Dubai Health Authority and Hamdan bin Mohammed Dental College

4.2. Population and location of study:

Fourteen patients (7 males and 7 females), aged 45-83 years (mean age 69.42 years), treated from March 2003 to March 2015 with implant-supported FDPs with a cantilever extension were included in the study. The implant sites included all mandibular and maxillary positions. Data recorded for all patients included the patient's: age, gender and smoking status. The implant data included: the diameter and length of the implant, age and region (FDI). The prosthesis data included: number, direction and length of cantilever pontics, and age.

Only 4 patients (3 males and 1 female) were treated in Hamdan bin Mohammed Dental College and all the others were treated in Albeda dental center, in Dubai Health Authority. The patients received 28 bridges, 18 with a distal cantilever and 10 with a mesial cantilever supported by at least two implants (some patients received more than one implant).

4.3. Inclusion criteria:

- Partial edentulism
- Implant-supported fixed dental prosthesis with at least one cantilever unit, which has been under functional loading a minimum of one year
- Smokers and non-smokers
- Controlled diabetes and Controlled hypertension

4.4. Exclusion criteria:

- Systemic diseases (such as heart, coagulation, and leukocyte diseases or metabolic disorders)
- A history of radiation therapy in the head and neck region.
- Current treatment with steroids
- Neurological or psychiatric handicap that could interfere with good oral hygiene
- Immuno-compromised status, including infection with HIV
- Severe clenching or bruxism
- Full-arch fixed prostheses
- Drug or alcohol abuse
- Poor attendance record.

4.5. Method of Data collection:

Data collection was carried out from patient records available in the software systems of Dubai Health Authority and Hamdan Bin Mohammed Dental College.

4.6. Sampling measures:

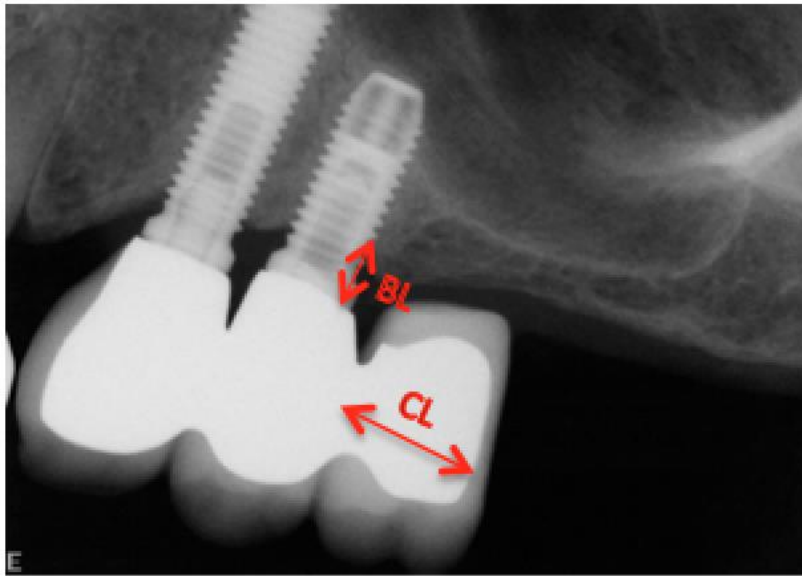
All the patients who had treatment at Dubai Health Authority and Hamdan bin Mohammed Dental College from March 2003 to March 2015 for implant-supported cantilever prostheses and met the inclusion criteria were selected for the study. Patient profiles included: age, gender, medical history, smoking status), implant evaluation (implant length, implant diameter, date of placement), as well as cantilever fixed dental prosthesis supported by implant (cantilever pontics number, cantilever length, date of loading and cantilever direction) were recorded.

Radiographic images were analyzed with a software program (Digora) to measure the following parameters:

- Cantilever length: from the most outer point of adjacent implant abutment crown to the most distal or mesial point of the cantilever pontic (figure 3)
- Peri-implant bone height: from the implant abutment to the crest of the peri implants bone. The implant that is adjacent to the cantilever pontic, on both mesial and distal aspects of the implant was assessed. Intraoral peri-apical radiographs were measured, first at baseline (time of implant loading) and second at the last follow-up appointment evaluation.

Bone loss was measured around the implant adjacent to the cantilever pontic to serve as a standard and compared to the actual implant length to correct for magnification error (figure 3). Bone loss = (Actual implant length x Distance from abutment to bone crest / Radiographical implant length)

Figure 3: Radiograph of cFDP showing measurement landmarks (BL: bone loss, CL: cantilever length)



4.7. Ethical Approval:

The Scientific Research Ethics Committee of Dubai Health Authority approved the study protocol. (Appendix 1)

5. Results

Fourteen patients were included in the study (7 males and 7 females), with a mean age of 69.42(9.03) years. The age range of the patients was between 45-83 years. All patients were rehabilitated with cantilever implant-supported fixed dental prostheses. A total of 44 implants were placed with a mean age of 3.72 years SD=(2.51). The implants supported 28 bridges with a mean age of 2.36 years SD= (2.59). The bridges consisted of 76 units including 32 cantilever units (Table 2).

Therefore, some of the bridges had multiple implants and more than 1 cantilever pontic. Most of the bridges, however, had just a single pontic. In addition, some of the patients had more than one cantilever fixed dental prosthesis.

Table 2: Descriptive variables in the study

Items	No.
No. Of patients (male/female)	14(7/7)
No. Of implants	44
No. Of Bridges	28
No. Of Cantilever units	32
Mean (SD) age of patient	69.42 (9.03)
Mean (SD) age of bridges	2.36 (2.59)
Mean (SD) age of implant	3.72 (2.51)

All implant material was titanium and all cantilever fixed dental prostheses were metal-ceramic. Twenty-eight cantilever implant-supported fixed dental prostheses were evaluated radiographically. The majority of the cantilever pontics were distally directed 23(71.9%), while 9(28.1%) were mesially directed.

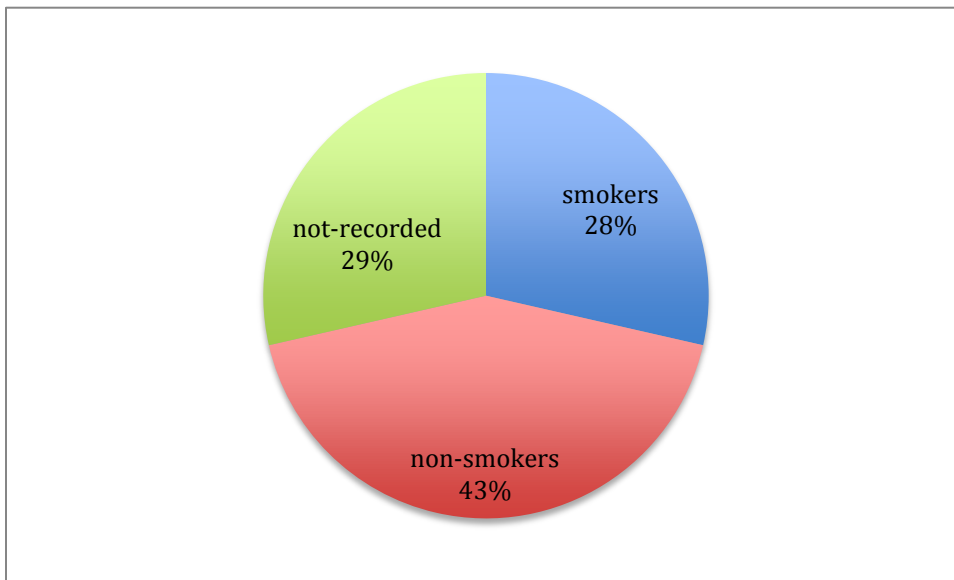
Ten (35.7%) cantilever FDPs were located in the upper right quadrant and 10(35.7%) in upper left quadrant. While 5(17.9%) located in lower right quadrant and 3(10.7%) in lower left quadrant. Table 3 shows the distribution of implants according to their position in the jaw (Table 3).

Table 3: Distribution of implant-supported cantilever prosthesis according to their position in the jaw (N=28)

Region implant/cantilever	No.(%)
Lower left	3 (10.7)
Upper left	10 (35.7)
Lower right	5 (17.9)
Upper right	10 (35.7)

Smoking habits are shown in (Figure 4). Most of the cases were non-smokers 43%, while 29% were not recorded.

Figure 4: Smoking status



5.1. Technical Complications:

Technical complications were recorded at all ages between 45-83 years. At prosthesis level, technical complications were recorded in 4 FDPs: Two with prosthesis loosening (7.1%) and 2 with de-cementation (7.1%). The 2 cases of prosthesis loosening occurred in males while prosthesis de-cementation occurred in 2 females. Two cases had de-cementation of the prosthesis (1 in upper right and 1 in upper left). While loosening occurred twice, both were in the lower jaw, 1 case in lower right and 1 in lower left (Table 4).

One of the 2 cases occurred in male, smoker, 9.5mm implant length and 3.5mm implant diameter and located in lower left quadrant. And the second case occurred in female patient, non-smoker, 11mm length of implant and 3.5mm implant diameter. Both were distal cantilevers, 1-year age of cantilever bridge and 2 years age of implant. In addition, de-cementation occurred in 2 cases, first case in male patient, non-smoker, 11mm length of implant and 3.5mm implant diameter, located in upper right quadrant and age of cantilever prosthesis and implant were 12-years and 13 years respectively. Second case of de-cementation was female patient, not-recorded smoking status; age of implant was 7 years and 6 years of cantilever prosthesis, located in upper left quadrant. Both were distal cantilever.

Table 4: Technical complications of bridges (N=28)

Technical complications	Absent (%)	Present (%)
Prosthesis loosening	26 (92.9)	2 (7.1)
De-cementation	26 (92.9)	2 (7.1)
Veneer chipping	28 (100)	0
Framework fracture	28 (100)	0

At the implant level, technical complications were mainly associated with implants of 9.5mm length and 3.5mm width except 1 case, which was 11mm implant length and 3.5mm width.

All screw-loosening of implant abutments occurred in males and in the upper jaw; 2 in right quadrant and 1 in left quadrant. From a total of 44 implants, only 3(6.8%) of implants had abutment-screw loosening (Table 5). Abutment screw-loosening occurred in 3 implants, all of them are in male patients, 1 was a smoker and the other 2 patients were not recorded smoking status. All of them had equal implant diameter (3.5mm) but different implant lengths. The cantilever length was between 5-9 mm, in all FDPs with implant abutment-screw-loosening.

All cases, which had technical complications, were distal cantilever prostheses. First case was 11mm length, in a non-smoker, placed in the upper right quadrant, cantilever prosthesis was 12 years old and implant was 13 years old. While Second and third cases

have almost same the characteristics, both had 9.5mm implant length and 3.5 mm implant diameter, distal direction of cantilever implant-supported prosthesis, but the smoking status was not-recorded. In both cases implants were placed in 2011 and loaded in the same year. Both cases were placed in the upper jaw, one in the right and one in the left quadrant.

Table 5: Technical complications of implants (N=44)

Technical complications	Absent (%)	Present (%)
Abutment screw-loosening	41 (93.2)	3 (6.8)
Implant screw-fracture	44 (100)	0
Implant fracture	44 (100)	0

Table 6: Comparison of implant screw-loosening between mesial and distal abutments on bridges according to whether 2 units or > 2 units fixed dental prostheses and cantilever direction

Technical complication		Distal Cantilever Direction		Mesial Cantilever Direction	
		2 units FDP	>2 units FDP	2units FDP	>2units FDP
Implant Screw-loosening	Present	1	2	0	0
	Absent	1	10	5	5
P-value 0.371					
$X^2 = 0.8$					

Table 7: Comparison of prosthesis de-cementation between mesial and distal cantilever prostheses:

Technical complication		Distal Cantilever Direction		Mesial Cantilever Direction	
		2 units FDP	>2units FDP	2units FDP	>2units FDP
Prosthesis Decementation	Present	1	2	0	0
	Absent	4	5	5	5
P-value 0.7353					
$X^2 = 0.1148$					

Table 8: Comparison of prosthesis loosening between mesial and distal cantilever prostheses:

Technical complication		Distal		Mesial	
		2 units FDP	>2 units FDP	2units FDP	>2units FDP
Prosthesis loosening	Present	1	2	0	0
	Absent	4	5	5	5
P-value 0.7353					
$X^2 = 0.1148$					

Most of the technical complications 5(71.4%) were associated with single cantilever pontic bridges supported by double implants, in contrast 1 case of prosthesis loosening occurred in single implant abutment supporting double cantilever pontics and 1 case of (implant abutment screw-loosening) occurred in single implant supporting single cantilever pontic. In addition, no complication occurred with double implants supporting a double cantilever (Figure 5). Nevertheless, all technical complication at prosthesis level occurred in FDPs with < 10 mm cantilever length (prosthesis de-cementation and prosthesis loosening).

Figure 5: Technical complication in relation to implant/cantilever number

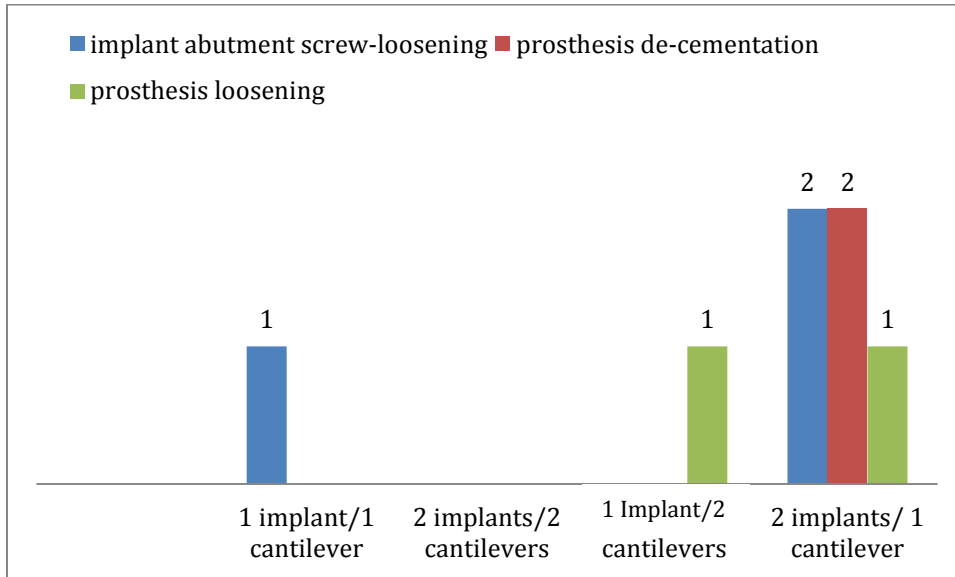
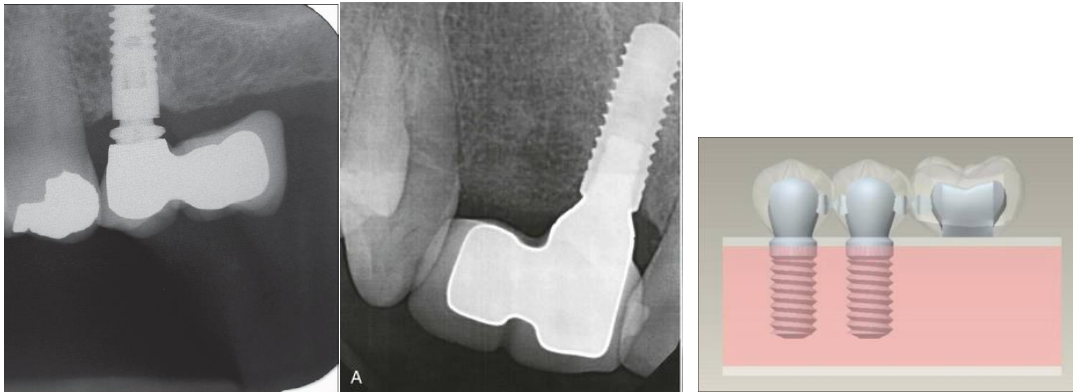


Figure 6: Radiographs shows single implant supporting double cantilever pontics (left), single implant supporting single cantilever pontic (middle) and image of double implants supporting single cantilever pontic (right)



5.2. Bone height changes:

From the total of 28 bridges, only 22 were available for radiographical analysis of bone height, while the rest of the patients missed their follow-up appointments and some of the follow-up radiographs were not clear. Marginal bone level was measured around implants at the time of prosthesis loading and at the last recorded recall appointment (Table 9).

Bone loss was tested for normality by using Kolmogorov-Sminov test. The data showed normal distribution of the bone loss data around both sides of implants adjacent to mesial and distal cantilevered pontics. Univariate analysis of variance was used to test for significance of bone loss around implants adjacent to mesially or distally directed cantilever and number of implant(s) (single or multiple).

Table 9: Marginal bone height from time of cantilever prostheses loading to the last recall visit

Table 10: Bone Loss Around Implants Supporting Distal Cantilever

Distal Cantilever						
Direction	Distal side of implant			Mesial side of implant		
Implant	N	Mean	SD	N	Mean	SD
Single	4	0.35	1.38	4	0.61	0.55
Multiple	8	0.93	10.09	8	1.24	0.85
Total	12	0.74	1.17	12	0.8	0.67

The mean of bone loss at distal side is lower than mesial side of implant supporting distal cantilevers (Table 10). However, there was no significant difference on bone loss at mesial and distal sides of implants adjacent to distal cantilvered pontic and ($P= 0.82$).

Table 11: Bone Loss Around implants Supporting Mesial Cantilever

Mesial cantilever						
Direction	Distal side of implant			Mesial side of implant		
Implant	N	Mean	SD	N	Mean	SD
Single	7	0.73	1.01	7	0.44	0.55
Multiple	3	1.01	0.79	3	1.15	0.77
Total	10	0.92	0.84	10	0.85	0.79

No significant difference was detected on bone loss with both sides mesial and distal around implants adjacent to mesial cantilevered pontic ($P = 0.533$). No statistical significant difference in marginal bone loss between mesial cantilever (P - value 0.53), and distal cantilever (P -value 0.82) on both sides of implant (Table 11).

Table 12: Comparison of marginal bone loss between mesial and distal cantilevers on mesial and distal sides of implant supporting cantilever unit(s)

Cantilever direction	Mesial cantilever		Distal cantilever	
	Distal side of implant	Mesial side of implant	Distal side of implant	Mesial side of implant
Implant-supporting cantilever				
Mean	0.91	0.76	0.73	0.8
SD	0.84	0.76	1.16	0.67
P-value	0.67		0.87	

There was 1 distal cantilever, which showed marginal bone loss >1 mm (1.52) and mesial and distal sides of implant adjacent to cantilever and technical complication (prosthesis loosening) in smoker male 73 years old. While 1 female 57 years old, non-smoker with no technical complications and 2 FDPs showed marginal bone loss > 1 mm, the distal cantilever (mesial: 2.17mm, distal: 3.08mm) marginal bone loss, and the mesial cantilever showed marginal bone loss (mesial: 2.23mm, distal: 0.58mm). Third case was female 62 years old, non-smoker with mesial cantilever, marginal bone loss was 1.19 mm in mesial and distal sides of implant supporting the cantilever unit.

All cases which recorded marginal bone loss > 1 mm occurred in prosthesis supported by implant with 9.5 mm length and 3.5 mm width. Two out of three cases showed bone loss

occurred in non-smoker patient. All marginal bone loss occurred in different age group, which showed no relation between patient age and marginal bone loss rate.

The number of implants placed to support the prosthesis and number of cantilevered pontics number (at least 1 implant) appeared to have significant impact on bone height. More than 1.2 mm bone loss was recorded around 1 implant supported 2-cantilever pontics. As well as, 2 technical complication of prosthesis (de-cementation, prosthesis loosening) recorded in (1 implant supported 2-cantilevers).

5.3. Gender:

Both technical complications of prosthesis loosening; 2 cases and De-cementation; 2 cases exist equally among gender. For abutment screw loosening the 3 cases were a male.

5.4. Age:

De-cementation complication occur on the youngest age 45 and 59 years

Prosthesis loosening occur on the above elder group age 62 and 73 years old

For the screw loosening the 3 cases had lower elder age 54, 59 and 67

5.5. Region:

For the abutment screw loosening all of them in maxilla 2 on right and 1 on left side

All of them were distal cantilevers

For the Decementation cases two were on maxilla and one on the right and one on the left

5.6. Implant Length and Diameter:

For the abutment screw loosening the average length is 10 (0.87) and the average of the diameter was 3.67 (0.289).

For the Decementation the average of the length of implant was 11 mm and the average of diameter was 4 mm.

For the prosthesis loosening the average length of implant was 10 mm and the average of diameter was 4 mm.

5.7. Age Of Cantilever prosthesis:

For the abutment screw loosening the average age of cantilever was 7 (0.33) and the average age of implant was 7.67 (4.62).

For the Decementation the average age of cantilever was 9 (4.25) and the average age of implant was 10 (4.24).

For the prosthesis loosening the average age of cantilever was 1 year and the average age of implant was 2 years.

6. Discussion:

Albrektsson et al¹² reported 1mm peri-implant bone loss during the first year of function, followed by an annual loss <0.2mm after the first year in service as a criteria for implant success. Albrektsson & Isidor¹³ also proposed the criterion for implant success and they suggested an average peri-implant marginal bone loss of less than 1.5 mm the first year after insertion of the prosthesis and less than 0.2 mm annual bone loss after that as a standard for successful therapy. In the present study implants had been in function for a mean of 48 months, minimal marginal peri- implant bone loss was reported with average less than 2 mm, which is considered as insignificant. Aligetta et al.⁷⁰ reported that the majority of studies showed that presence of cantilever extensions does not affect negatively on marginal bone height⁷⁰. Although the data was limited, drawing a definitive conclusion from such study is problematic, as well as, other factors should be considered important such as: periodontal status, smoking status and the presence of adequate plaque control. In general, causes of marginal bone loss depend on patient factors and implant design factors. Nevertheless, smoking had a determined effect on peri-implant bone loss³⁹. In contrast, in the present study, none of the smokers showed more than 1 mm bone loss or any technical complication, although 29% of the cases were not reported and most probably they are smokers (figure 4).

In our study, the radiographical examination was done on the existing radiographs at the time of implant loading and at last follow-up visit. Most of the patients who completed their treatment for more than 5 years are not attending regularly for follow-up visits. There are many reasons for missing follow-up visits at Dubai Health Authority. First,

most of the patients are elderly, poorly educated, and not aware of the importance of maintenance and follow-up visits. Second, since they do not have pain or symptoms of discomfort, they refused to attend for maintenance.

Smoking tobacco has been shown to have a deleterious effect on both osseointegration and crestal bone loss, Bain 1996⁷¹. Our results indicate that smokers do not show more crestal bone loss than non-smokers, however, these finding should be interpreted with caution, as only 22.2% of the implants included in our study were placed in non-smokers.

It has been demonstrated that a higher incidence of biologic and prosthetic complications was expected for cantilever FDPs, when compared with those without cantilevers⁷², as claimed that cantilever extension increases the risk of flexion overload, and consequently compromise the prognosis of prosthetic rehabilitation. Further, in term of cantilever length. A clinical study demonstrated that long cantilevers (≥ 15 mm) induced more implant-prostheses failures compared to cantilevers < 15 mm long⁵⁰. The above study indicated that a shorter cantilever length is more favorable for the success of implant-supported prostheses, particularly for prostheses with fewer implants. In current study, all technical complication recorded with cantilever length less than 10 mm and (2-cantilever supported by 1 implant).

The present data indicated that technical complications are uncommon with cantilever FDPs. The present study demonstrated that cantilever implant-supported fixed dental prosthesis directed mesial/distal to implant restoration causes minor technical complication such as abutment screw-loosening, prosthesis de-cementation and prosthesis loosening. Further, no implant failure has been recorded. In present data the

number of patients was limited, which has equally distributed, 7 males and 7 females. Screw-loosening of abutments N= 3 (0.7%) and prostheses de-cementation N= 2 (7.4%), occurred in implants placed at least 5 years beforehand. On the other hand, 2 cases that showed prosthesis loosening, the implants were placed in 2014 and loaded in 2015. These results corroborate the most frequently cited technical complications for cantilever implant-supported fixed dental prostheses, which were veneer fracture, screw loosening and loss of retention⁵⁵. It has been shown that the mere presence of a cantilever extension does not increase the mechanical/ technical risks for implants supporting short span cantilever FDPs³. According to our observations, distal or mesial bone loss on implant adjacent to cantilevered units was not statistically different if the cantilever pontic mesial or distal directed.

The marginal bone loss could be influenced by many factors and that it is not limited only to the presence/absence of a cantilever extension^{45,54}. Another confounding factor that might be considered when assessing peri-implant bone loss is the crown-implant ratio⁵⁶, which leads to misleading results. Recent studies claimed that prosthesis height does not influence the crestal stress concentration, as displayed by no significantly greater marginal bone loss⁵⁸. Thus, assessing contributing factors for marginal bone loss display show limitations because many confounding elements are may be present and thus difficult to assess⁶⁰. Our results also suggest that the use of single-unit cantilevered extensions in the distal aspect of the implant restorations may influence technical complications at implant and prostheses level. Only one implant placed in 2011 and loaded in 2012 showed a mesial bone loss in 2015 around 1 implant and the grade III mobility. The reason as recorded was poor oral hygiene. With maintenance, the mobility

reduced to grade I at last follow up visit. Also from the ethical point of view, it is not allowed to take further radiograph for research analysis purpose so that not all cases were measured accurately. Moreover, regarding the data that collected from Dubai Health Care Authority most of the cases are done in periodontics department so that most of the prosthetical details are missing or not recorded. It is difficult to collect all required information in the retrospective study because of missing data in the clinical notes. These records should be viewed with caution since our study did not report on large sample size and our data depended mainly on the clinical records, which were not well recorded.

In the present study, no significant bone loss was formed for implants with a mean age of 48 months. In cases that showed around 2 mm bone loss; this 2 mm bone loss was a cumulative amount after 2 years of loading cantilever prostheses. While the majority showed no excessive marginal bone loss, which was in agreement with some studies, particularly Aglietta et al. 2012⁷⁰, bone level changes in the posterior maxilla and mandible and also concluded no difference between cantilever and non-cantilever implants, even when small FDPs were compared with implants supporting single crowns with cantilever.

Stress distribution in the surrounding bone has been reported to depend on the dimensions of the implant⁷³, which directly affects the area of possible bone retention. It has been recommended that implants to be as long and as wide as possible within the anatomic limitations of the patient⁷⁴. Although a number of investigators reported higher rates of bone loss in shorter implant⁷⁵ length and the importance of implant length in sustaining the load of fixed restorations has been pointed out⁷⁶. There are also studies

where implant length was reported to have little influence on the amount of stress in vertical loading and to have a smaller effect on stress distribution in the bone than the implant diameter⁷⁷, finite element method (FEM) analysis of implants has shown stress reduction with increasing diameter and radiographically measured bone loss for 4.0-mm diameter implants has been found to be less than 3.5-mm¹⁴. However, in the present study, 9.5 mm implant length and 3.5 mm width of the implant caused a significant impact on MBL as well as the technical complications.

No major detrimental effects with respect to peri-implant tissues were observed at implants in the proximity of cantilever extensions. However, in another recent systematic review it was pointed out that the incorporation of cantilevers into implant-borne prostheses might be associated with a higher incidence of minor technical complications⁷⁸.

7. Conclusion:

- (1) Within the limitation of this study, marginal bone loss does not seem to be influenced by the presence of cantilever extensions mesial or distal.
- (2) Moreover, minor implant technical complications were found when a distal cantilever was present (screw-loosening, prosthesis de-cementation and prosthesis loosening).
- (3) Most of technical complications were associated with 9.5mm implant length and 3.5mm width, which represent the majority of included implants.

8. Data collection: Case Report Form

8.1. Personal profile

- Age:
- Gender:
- Medical record:
- Smoker/ non-smoker:
- Para functional habits:
- Periodontal status:

8.2. Implant evaluation

- Implant position & region: FDI#
- Number of implant(s):
- Implant material: Titanium/ ceramic / others
- Implant restoration fixation: screw-retained/ cemented
- Implant design: parallel/ tapered / one piece / two piece
- Implant length:
- Implant diameter:
- Date of delivery of implant (year):
- Implant – Abutment connection type:
- Implant placed by: GP / Specialist

8.3. Prosthesis:

- Prosthesis material: MC / all ceramic
- Prosthesis extension type: mesial / distal
- Crown units/implant ratio:
- Date of delivery:
- Prosthesis delivered by: GP / specialist
- Length of cantilever (mm):
- FDP Supported by:
- No of units supporting FDP:

9. Bibliography:

1. Jokstad A., Braegger U., Brunski J.B., Carr A.B., Naert I., Wennerberg A., Koutsikakis G., Duyck J., Quirynen M., Jacobs R. & van Steenberghe D. Quality of dental implants biologic outcome of implant-supported restorations in the treatment of partial edentulism, Part I: a longitudinal clinical evaluation. *International Dental Journal* 2003; 53: 409–443.
2. Buser D., Mericske-Stern R., Bernard J.P., Behneke A., Behneke N., Hirt H.P., Belser U.C. Lang, N.P. Long-term evaluation of non-submerged ITI implants. Part 1: 8-year life table analysis of a multi-center study with 2359 implants. *Clinical Oral Implant Research* 1997a; 8: 161–172.
3. Pjetursson BE, Thoma D, Jung R., Zwahlen M, Zembic A. A systematic review of the survival and complication rates of implant-supported fixed dental prostheses (FDPs) after a mean observation period of at least 5 years, *Clin. Oral Implants Res* 2012; 23(Suppl. 6), 22–38.
4. Pjetursson B.E., Tan K., Lang N.P., Braegger U., Egger M., Zwahlen M. A systematic review of the survival and complication rates of fixed partial dentures (FDPs) after an observation period of at least 5 years. *Clinical Oral Implants Research* 2004; 15: 625–42.
5. Pjetursson B.E., Lang N.P. Prosthetic treatment planning on the basis of scientific evidence. *Journal of Oral Rehabilitation* 2008; 35 (Suppl. 1): 72–79.
6. Benic G.I., Mokti M., Chen C.J., Weber H.P., Hammerle C.H., Gallucci, G.O. Dimensions of buccal bone and mucosa at immediately placed implants after 7

- years: a clinical and cone beam computed tomography study. *Clinical Oral Implants Research* 2011; 23: 560–566.
7. Goodacre CJ, Bernal G, Rungcharassaeng K, Kan JY. Clinical complications with implant and implant prostheses. *J Prosthetic Dent* 2003; 90:121–132.
 8. Lekholm U., Gunne J., Henry P., Higuchi K., Linde´n U., Bergstro¨m C., van Steenberghe, D. Survival of the Braˆnemark implant in partially edentulous jaws: a 10-year prospective multicenter study. *International Journal of Oral and Maxillofacial Implants* 1999; 4: 639–645.
 9. Papaspyridakos P., Shen C. J., Chuang S. K., Weber H.P., Gallucci G.O. A Systematic Review of Biologic and Technical Complications with Fixed Implant Rehabilitations for Edentulous Patients. *The International Journal of Oral and Maxillofacial Implants* 2012; Vol. 27 Issue 1, p102-110. 9p.
 10. Albrektsson T., Sennerby L. State of the art in oral implants. *Journal of Clinical Periodontology* 1991; 18: 474-481.
 11. Branemark P.I., Adell R, Breine U., Hansson B.O., Lindstrom J. Ohlsson A. Intraosseus anchorage of dental prostheses. Experimental Studies. *Scandinavian Journal of Plastic Reconstructive Surgery* 1969; 3: 81-100
 12. Albrektsson T, Zarb G, Worthington P, Eriksson RA. The long-term efficacy of currently used dental implants: a review and proposed criteria of success. *Int J Oral Maxillofac Implants* 1986; 1:11-25.
 13. Albrektsson T, Isidor F. Consensus reports session IV. In: Lang NP, Karring T, editors. *Proceedings of the European Workshop on Periodontology*. London, Quintessence 1993; 365-369

14. Ivanoff C.J., Widmark G., Hallgren C., Sennerby L., Wennerberg A. Histologic evaluation of the bone integration of TiO₂ blasted and turned titanium micro-implants in humans. *Clinical Oral Implants Research* 2001; 12: 128-134.
15. Schwarz M.S. Mechanical complications of dental implants. *Clinical Oral Implants Research* 2000; 11; 1: 156-158.
16. Carlson L., Rostlund T, Albrektsson B., Albrektsson T. Removal torques for polished and rough titanium implants. *International Journal of Oral Maxillofacial Implants* 1988; 3: 21-24.
17. Feighan J.E., Goldberg V.M., Davy D., Parr J.A., Svensson S. The influence of surface blasting on the incorporation of titanium-alloy implants in a rabbit intramedullary model. *Journal of Bone and Joint Surgery* 1995; 77-A: 1380-1395.
18. Carlsson, G. E., Lindquist, L. W., and Jemt, T. Long-term marginal peri-implant bone loss in edentulous patients. *Int J Prosthodontics* 2000; 13: 295-302.
19. WinterGreen Research, I. Worldwide Nanotechnology Dental Implant Market Shares, Strategies, and Forecasts, 2009 to 2015. 2009.
20. Schwartz N. L., Whitsett L. D., Berry T. G., and Stewart J. L. Unserviceable crowns and fixed partial dentures: life-span and causes for loss of serviceability. *J Am Dent Assoc.* 1970; 81: 1395-1401.
21. Carr A. B., Laney W.R. Maximum occlusal force levels in patients with osseointegrated oral implant prostheses and patients with complete dentures. *Int J Oral Maxillofacial Implants* 1987; 2: 101-108.

22. Buser D., Martin W., Belser U. C. Optimizing esthetics for implant restorations in the anterior maxilla: anatomic and surgical considerations. *Int J Oral Maxillofacial Implants* 2004; *19 Suppl*: 43-61.
23. Schropp L., Wenzel A., Kostopoulos L., Karring T. Bone healing and soft tissue contour changes following single-tooth extraction: a clinical and radiographic 12-month prospective study. *Int J Periodontics Restorative Dent* 2003; *23*: 313-323.
24. Branemark P, Zarb G, Albrektsson T: *Tissue-Integrated Prostheses Osseointegration in Clinical Dentistry*. Chicago, Quintessence Publishing Co. Inc. 1985; Volume 54, Issue 4, Pages 611–612
25. Albrektsson T, Hansson H, Kasemo B, Larsson K, Lundstrom I, McQueen D, Skalak R: The interface of inorganic implants in vivo; Titanium implants in bone. *Annals of Biomedical Engineering* 1983; *11*:1-27.
26. Masuda T, Yliheikkila P, Felton D, Cooper L: Generalizations Regarding the Process and Phenomenon of Osseointegration. Part I. In Vivo Studies. *The International Journal of Oral and Maxillofacial Implants* 1998; *13*:17-29.
27. Davies J. Mechanisms of Endosseous Integration. *International Journal of Prosthodontics* 1998; *11*:391-401.
28. Williams DF. Implants in dental and maxillofacial surgery. *Biomaterials* 1981; *2*:133-136.
29. Lemons JE. Dental implant biomaterials. *J Am Dental Assoc* 1990; *121*:716-719.
30. Brånemark PI, Adell R, Albrektsson T, Lekholm U, Lundkvist S, Rockler B: Osseointegrated titanium fixtures in the treatment of edentulousness. *Biomaterials* 1983; *4*:25–28

31. Meffert RM, Langer B, Fritz ME: Dental implants: a review. *J Periodontal* 1992; 63:859–870
32. Lautenschlager EP, Monaghan P. Titanium and titanium alloys as dental materials. *Int Dental J* 1993 Jun; 43(3):245-53.
33. Schroeder A, Van der Zupen E, Stich H, Sutter F. The Reactions of Bone, Connective Tissue and Epithelium to Endosteal Implants with Titanium Sprayed Surfaces. *Journal of Oral and Maxillofacial Surgery* 1981; 9:15-25.
34. Zarb G, Albrektsson T. Guest Editorial: Osseointegration: A Requiem for the Periodontal Ligament? *The International Journal of Periodontics & Restorative Dentistry* 1991; 11:88-91.
35. Albrektsson T, Johansson C, Sennerby L. Biological aspects of implant dentistry: osseointegration. *Periodontology* 2000; 4:58-73.
36. Akagawa Y, Wadamoto M, Sato Y, Tsuru H. The three-dimensional bone interface of an osseointegrated implant: A method for study. *The Journal of Prosthetic Dentistry* 1992; 68:813-816.
37. Wadamoto M, Akagawa Y, Sato Y, Kubo T. The three-dimensional bone interface of an osseointegrated implant. I: A morphometric evaluation in initial healing. *The Journal of Prosthetic Dentistry* 1996; 76:170-175.
38. Mumcu E, Bilhan H, Cekici A. Marginal Bone Loss Around Implants Supporting Fixed Restorations, *Journal of Oral Implantology* 2011; 37: 549-559
39. Fransson C., Wennstrom J., Berglundh T. Clinical characteristics at implants with a history of progressive bone loss. *Clinical Oral Implants Research* 2008; 19: 142-147.

40. Roos-Jansaker A-M., Renvert H., Lindahl Ch., Renvert S. Nine to fourteen-year follow-up of implant treatment. Part III: factors associated with peri-implant lesions. *Journal of Clinical Periodontology* 2006; 33: 296-301.
41. Rita C., Munniswamy K., Natural tooth Versus Implant, *Journal of Oral Implant.* Vol. XXX VIII/No. One/2012; 95-100
42. Parfitt A.M., Bone Histomorphology: standardization of nomenclature, symbols, and units. Report of the ASBMR Histomorphometry NoNomenclature Committee. *Journal of Bone and Mineral Research* 2:595-610
43. Romeo E., Storelli S. Systematic review of the survival rate and the biological, technical and esthetic complications of fixed dental prostheses with cantilevers on implants report edin longitudinal studies with a mean of 5 years follow-up. *Clin. Oral Implants Res* 2012; 23(Suppl. 6) 39–49
44. Naert I., Quirynen M., Vansteenbergh D., Darius P. A study of 589 consecutive implants supporting complete fixed prostheses 2. Prosthetic aspects. *Journal of Prosthetic Dentistry* 1992; 68: 949–956.
45. Bragger, U., Hirt-Steiner, S., Schnell, N., Schmidlin, K., Salvi, G.E., Pjetursson, B., Matuliene, G., Zwahlen, M. & Lang, N.P. Complication and failure rates of fixed dental prostheses in patients treated for periodontal disease. *Clinical Oral Implants Research* 2011; 22: 70–77.
46. Nedir R., Bischof M., Szmukler-Moncler S., Belser U.C., Samson J. Prosthetic complications with dental implants: from and up-to-8-year experience in private practice. *The International Journal of Oral & Maxillofacial Implants* 2006; 21: 919–928.

47. Romeo E., Lops D., Margutti E., Ghisolfi M., Chiapasco M. & Vogel G. Long-term survival and success of oral implants in the treatment of full and partial arches: a 7-year prospective study with the ITI dental implant system. *The International Journal of Oral & Maxillofacial Implants* 2004; 19: 247–259.
48. Rangert B.R., Sullivan R.M., Jemt T.M. Load factor control for implants in the posterior partially edentulous segment. *International Journal of Oral & Maxillofacial Implants* 1997; 12: 360–370.
49. Lindquist L.W., Carlsson G.E., Jemt T. A 15-year follow-up study of mandibular fixed prostheses supported by osseointegrated implants. *Clinical Oral Implants Research* 1996; 7: 329-336.
50. Shackleton JL, Carr L, Slabbert JC, Becker PJ. Survival of fixed implant-supported prostheses related to cantilever lengths. *J Prosthetic Dent* 1994; 71: 23-26.
51. Duyck J, Van Oosterwyck H, Vander Sloten J, De Cooman M, Puers R, Naert I. Magnitude and distribution of occlusal forces on oral implants supporting fixed prostheses: an in vivo study. *Clin Oral Implants Res* 2000; 11: 465-475.
52. Yi-Bing Wang. Implant occlusion: biomechanical considerations for implant-supported prostheses, Department of Dentistry, Tri-Service General Hospital 2008; No. 325, *J Dent Sci* · Vol 3 · No 2
53. Misch CE. Occlusal considerations for implant-supported prostheses: implant-protective occlusion. In Misch CE ed “Dental Implant Prosthetics” 1st ed, Elsevier Mosby, St. Louis, pp. 472-510, 2005.

54. Kim P, Ivanovski S, Latcham N, Mattheos N. The impact of cantilevers on biological and technical success outcomes of implant-supported fixed partial dentures. A retrospective cohort study. *Clin. Oral Impl. Res.* 2014; 25, 175–184
55. Halg GA, Schmid J, Hammerle CH. Bone level changes at implants supporting crowns or fixed partial dentures with or without cantilevers. *Clin Oral Implants Res* 2008; 19:983–990.
56. Zurdo J, Romao C, Wennström JL. Survival and complication rates of implant-supported fixed partial dentures with cantilevers: A systematic review. *Clin Oral Implants Res* 2009; 20(suppl 4):59–66.
57. Torrecillas-Martinez L, Monje A, Lin G, Suarez F, Ortega-Oller I, Galindo-Moreno P, Wang H. Effect of cantilevers for implant-supported prostheses on marginal bone loss and prosthetic complications: Systematic review and meta-analysis. *Int J Oral Maxillofacial Implants* 2014; 29(6): 1315–21.
58. Romeo E, Tomasi C, Finini I, Casentini P, Lops D. Implant-supported fixed cantilever prosthesis in partially edentulous jaws: A cohort prospective study. *Clin Oral Implants Res* 2009; 20:1278–1285.
59. Blanes RJ, Bernard JP, Blanes ZM, Belser UC. A 10-year prospective study of ITI dental implants placed in the posterior region. II: Influence of the crown-to-implant ratio and different prosthetic treatment modalities on crestal bone loss. *Clin Oral Implants Res* 2007; 18:707–714.
60. Garaicoa-Pazmino C, Suarez F, Monje A, et al. Influence of crown- implant ratio upon marginal bone loss. A systematic review. *J Periodontol* 2014 Jan 20.


61. Martin, W., Lewis, E. & Nicol, A. Local risk factors for implant therapy. *International Journal of Oral & Maxillofacial Implants* 2009; 24: 28–38.
62. Tarnow D.P., Cho S.C., Wallace S.S. The effect of inter-implant distance on the height of inter-implant bone crest. *Journal of Periodontology* 2000; 71: 546–549.
63. Tarnow D., Elian N., Fletcher P., Froum S., Magner A., Cho, S.C., Salama M., Salama H., Garber D.A. Vertical distance from the crest of bone to the height of the interproximal papilla between adjacent implants. *Journal of Periodontology* 2003; 74: 1785–1788.
64. Stegaroiu R., Sato T., Kusakari H., Miyakawa O. Influence of restoration type on stress distribution in bone around implants: A three-dimensional finite element analysis. *The International Journal of Oral & Maxillofacial Implants* 1998; 13: 82–90.
65. Rodriguez A.M., Aquilino S.A., Lund P.S., Ryther J.S., Southard T.E. Evaluation of strain at the terminal abutment site of fixed mandibular implant prosthesis during cantilever loading. *Journal of Prosthodontics* 1993; 2: 93–102.
66. Chambrone L., Chambrone L.A., Lima L.A. Effects of occlusal overload on peri-implant tissue health: A systematic review of animal-model studies. *Journal of Periodontology* 2010; 81: 1367–1378.
67. Aglietta M., Siciliano V.I., Zwahlen M., Bragger U., Pjetursson B.E., Lang N.P., Salvi, G.E. A systematic review of the survival and complication rates of implant supported fixed dental prostheses with cantilever extensions after an observation period of at least 5 years. *Clinical Oral Implants Research* 2009; 20: 441–451.


68. Pjetursson BE, Tan K, Lang NP, Bragger U, Egger M, Zwahlen M. A systematic review of the survival and complication rates of fixed partial dentures (FPDs) after an observation period of at least 5 years. *Clin Oral Implants Res* 2004; 15:667–676.
69. Wennstrom J., Zurdo J., Karlsson S., Ekestubbe A., Grondahl K., Lindhe J. Bone level change at implant-supported fixed partial dentures with and without cantilever extension after 5 years in function. *Journal of Clinical Periodontology* 2004; 31: 1077–1083.
70. Romeo E, Lops D, Margutti E, Ghisol M, Chiapasco M, Vogel G. Implant-supported fixed cantilever prostheses in partially edentulous arches. A seven-year prospective study. *Clin Oral Implants Res* 2003; 14:303–311.
71. Aglietta M., Iorio Siciliano, V., Blasi, A., Sculean, A., Bragger U., Lang N.P., Salvi G.E Clinical and radiographic changes at implants supporting single-unit crowns (SCs) and fixed dental prostheses (FDPs) with one cantilever extension. A retrospective study. *Clinical Oral Implants Research* 2012; 23: 550–555.
72. Bain, C.A., Smoking and Implant Failure Benefit of A Smoking Cessation Protocol. *Int J Oral Maxillofacial Implants* 1996; Vol. 11 Issue 6, P 765-759.
73. Jemt T, Carlsson L, Boss A, Jörneus L. In vivo load measurements on osseointegrated implant supporting fixed or removable prostheses: A comparative pilot study. *Int J Oral Maxillofacial Implants*. 1991; 6:413-417.
74. Pilliar R.M., Deporter D.A., Watson P.A., Valiquette N. Dental implant design: effect on bone remodeling. *J Biomed Mater Res*. 1991; 25:467–483.

75. Winkler S, Morris HF, Ochi S, Implant survival to 36 months as related to length and diameter. *Ann Periodontol* 2000; 5:22–31.
76. Bahat O. Treatment planning and placement of implants in the posterior maxillae: report of 732 consecutive Nobelpharma implants. *Int J Oral Maxillofacial Implants*. 1993; 8:151–161.
77. Kunavisarut C, Lang LA, Stoner BR, Felton DA. Finite element analysis on dental implant-supported prostheses without passive fit. *J Prosthodont*. 2002; 11:30–40
78. Himmlova L, Dostalova T, Kacovsky A, Konvickova S. Influence of implant length and diameter on stress distribution: a finite element analysis. *J Prosthet Dent*. 2004; 91:20–25.
79. Mumcu E., Bilhan H., Cekici. A., Marginal Bone Loss Around Implants Supporting Fixed Restorations. *J Of Oral Implantology* 2011 Oct; 37(5): 549-58.

10. APPENDIX

10.1 Ethics approval letter from DHA

 **DUBAI SCIENTIFIC RESEARCH ETHICS COMMITTEE**
APPROVAL LETTER

 **هيئة الصحة بدبي**
DUBAI HEALTH AUTHORITY

From :	Dubai Scientific Research Ethics Committee (DSREC) Dubai Health Authority	Date :	01 May 2016
To :	Ms. Hayat TareeshAlaleeli, Hamdan Bin Mohammed College of Dental Medicine	Ref :	DSREC-SR-05/2016_02
Study Site	Dental Department in Dubai Health Authority		

Subject: Approval for the research proposal, **"The impact of cantilevers position on clinical outcome of implant-supported fixed dental prosthesis."**

Dear Ms. Hayat TareeshAlaleeli,

Thank you for submitting the above mentioned research proposal to Dubai Scientific Research Ethics Committee, DHA. Dubai Scientific Research Ethics Committee has been organized and operates in accordance with the ICH/GCP guidelines.

Your request was discussed with Dubai Scientific Research Ethics Committee. We are pleased to advise you that the committee has granted ethical approval for the above mentioned study to be conducted in Dubai Health Authority. However, you will have to approach the Medical Director of the Hospitals to secure permission to review any hospital records and to carry out your study in the hospital.

Please note that it is DSREC's policy that the principal investigator should report to the committee of the following:

1. Anything which might warrant review of ethical approval of the project in the specified format, including:
 - any serious or unexpected adverse events and
 - unforeseen events that might affect continued ethical acceptability of the project
2. Any proposed changes to the research protocol or to the conduct of research
3. Any new information that may affect adversely the safety of the subjects
4. If the project is discontinued before the expected date of completion (reason to be specified)
5. Annual report to DSREC about the progress of the study
6. A final report of the finding on completion of the study

Please note that this approval is valid for **one year** from the date of this letter. It is your responsibility to ensure that an application for continuing review approval has been submitted at the required time.

