

See discussions, stats, and author profiles for this publication at: <https://www.researchgate.net/publication/285734055>

# 10 X INDIAN JOURNAL OF APPLIED RESEARCH Surgical Treatment of Obstructive Sleep Apnoea Hypopnoea Syndrome: Review Medical Science

Article in Indian Journal of Applied Research · December 2015

CITATIONS

0

READS

74

1 author:



**Adil Osman Mageet**

Ajman University

38 PUBLICATIONS 39 CITATIONS

SEE PROFILE

Some of the authors of this publication are also working on these related projects:



How to correctly assessing final year dental srudents [View project](#)



immediate effect of twin block functional appliance of the hyoid bone position [View project](#)



## Surgical Treatment of Obstructive Sleep Apnoea Hypopnoea Syndrome: Review

### KEYWORDS

Sleep apnoea, Hyoid bone suspension, geniotubercle advancement, bimaxillary surgery

### Mageet AO

Department of Orthodontics, HBM College of Dental Medicine, Mohammed Bin Rashid University of Medicine and Health Sciences, Dubai, UAE

### ABSTRACT

Obstructive Sleep Apnoea Hypopnoea Syndrome is a life threatening breathing disorder, caused by repeated upper airway occlusion during sleep. There are wide ranges of treatment procedures. This review article intends to facilitate the understanding of the non-surgical treatment of this disorder.

In the treatment of OSAHS, surgical approaches have been proposed for identified levels of obstruction. Medical approaches are more commonly used; but not all patients are able or willing to conform to medical treatment. This group may be candidates for surgical intervention directed at the anatomical regions involved. During assessment of the patient, a surgical option can be considered, particularly in younger or middle-aged subjects, who may wish to avoid a period of attachment to CPAP or alternative medical devices.

Pre-surgical evaluation is important, in order to identify the type of anatomic abnormality present and the severity of the OSAHS. This will entail not only overnight polysomnography but also other investigations, such as cephalometric analysis, sleep nasendoscopy and three-dimensional MRI. The American Sleep Disorders Association has produced recommendations for the use of surgical procedures in OSAHS. Desired treatment outcomes include resolution of the clinical signs and symptoms of OSAHS and normalisation of the apnoea / hypopnoea index and oxyhaemoglobin saturation levels. Because of the complexity of airway narrowing or collapse during sleep, any one surgical procedure may not eradicate a patient's sleep apnoea. A stepwise approach to the surgical management would be acceptable if the patient is advised at the onset of treatment about the likelihood of the success of each procedure and that multiple operations may be necessary. Once the surgical site has healed, follow-up evaluation, including an objective measure of respiration and quality of sleep, must be performed to ensure that the abnormalities noted in the original study have been corrected.

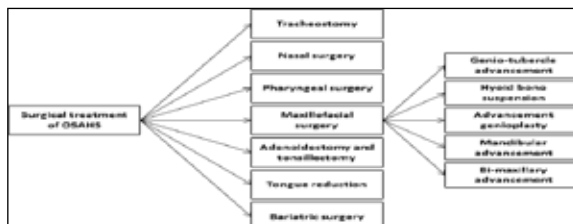


Figure 1. Surgical techniques for OSAHS

Historically, the first surgical modality employed for the management of OSAHS was the tracheostomy, which proved effective in bypassing the impaired pharyngeal airway (Guyette RF and Waite PD, 1995).

Although improvement of the manifesting symptoms associated with the OSAHS condition is dramatic, patients may discover a whole new set of problems post operative. These problems, which are associated with the surgical procedure, include bleeding, stoma, narrowing and granulation tissue formation.

Kim et al., (1998) undertook a retrospective study of all patients who had received a tracheostomy and who had been subjected to polysomnography since 1981 at the Johns Hopkins Sleep Disorder Centre. They concluded that tracheostomy effectively treated patients with 'uncomplicated' OSAHS but was considerably less effective in the treatment of patients with overlying cardiopulmonary decompensation.

Conway et al., (1981) published an article on the adverse effects of tracheostomy in which they highlighted the fact that a number of patients who had undergone tracheostomy experienced tracheal granular malformation or stomal stenosis, necessitating revision procedures.

This, coupled with the considerable social disadvantage of the operation, means that tracheostomy for OSAHS is generally only used as a last resort, never as a treatment of first choice (Meyer JB and Knudson RC., 1990).

The problems associated with the procedure have effectively relegated to the history books; however, in severe cases of OSAHS, which may be considered as life threatening, the tracheostomy may still be utilized as a final resort to treatment (Meyer JB and Knudson RC, 1990).

Postoperative wound infection and recurrent purulent bronchitis requiring hospitalization and / or antibiotics have been seen to occur, and reported psychological problems have include depression, substance abuse and marital problems (Conway et al., 1981).

Tracheostomy should only be considered when all else fails in carefully selected individual (SIGN, 2003).

The presence of **nasal obstruction** can both exacerbate the symptoms of OSAHS and inhibit optimal use of CPAP; common indications for nasal surgical reconstruction are: septal deviation, turbinate hypertrophy, nasal polyps or chronic nasal congestion.

There is a considerable variety of opinion in the literature as to the efficacy of relieving nasal obstruction in OSAHS, with Olsen and Kern (1990) concluding that relief of nasal obstruction does not resolve OSAHS whilst EL-Sharif I and Hussein SN (1998) reported that 50% of 96 patients in their study obtained total relief, with a further 40% gaining some improvement.

Kuna and Sant' Amriggio (1991) recommended that intranasal procedures were useful in facilitating other non-surgical treatment regimens like nasal continuous positive airway pressure (nCPAP). This view is supported by Freidmann et al., (2000) who, in study of 50 consecutive patients with nasal airway obstruction and OSAHS, reported that although there was some improvement in nasal airway resistance, nasal surgery did not consistently improve the situation but may have contributed to a decrease in the required nCPAP pressure level and hence an improvement in oxygen saturation.

McDonald JP, (2003) in his review article concluded that intranasal surgical intervention is unpredictable in its effect on OSAHS. The Scottish Intercollegiate Guidelines Network report (2003) on OSAHS recommended that alternative surgical approaches to OSAHS are experimental and should not be used outside the context of a randomised clinical trial (RCT).

The most widely used surgical treatment for Obstructive Sleep Apnoea / Hypopnoea Syndrome (OSAHS) and indeed snoring, is **uvulo-palato-pharyngoplasty (UPPP)**, the original procedure was proposed by Ikematsu T, (1964), who reported on 152 patients with 82% relief from snoring. The technique was then introduced into the USA by Fujita S et al., (1981) as an alternative to tracheostomy, he also suggested that anatomical indications for UPPP were a long uvula, redundant pharyngeal wall tissue, and / or excess tonsillar tissues.

The procedure was initially devised to excise the uvula, the tonsils (if present), and portion of the soft palate, and to reorientate the tonsillar pillars in order to enlarge the oropharyngeal space, and therefore decrease pharyngeal collapsibility (Riley et al., 1987).

UPPP originally undertaken by surgical excision, more commonly now utilising a laser (LAUP) (Kamami et al., 1994).

The rationale behind such procedure follows that if the soft palate is large and found to be the cause of pharyngeal obstruction, then its virtual removal would prove curative.

Although subjectively it was thought to be curative procedure to many oto-rhino-laryngologists and their patients, the actual success rate for the procedure has been suggested to only 40.7% (Sher et al., 1995).

Successful surgery was defined as a reduction in AHI to <10 or to <20 with a 50% reduction from the patients' baseline AHI.

A mandibular-hyoid distance (MP-H) >20mm post-surgery was found to be significantly ( $P=0.05$ ) predictive of failure of UPPP (Millman RP et al., 2000). The distance between the superior points of a line-constructed plane of the sphenoidale (Parallel to Frankfurt Horizontale) and a point at the intersection of the palatal plane perpendicular to the hyoid correlated negatively with post-surgical AHI. An MP-H distance of <21mm, an angle created by point 'A' to

Nasion to point 'B' <3, and the presence of baseline AHI >38 enhanced the predictability of UPPP success (Millman et al., 2000).

Walker-Engstrom et al., (2002) studied ninety-five patients with mild to moderate obstructive sleep apnoea / hypopnoea syndrome (Apnoea Hypopnoea Index AHI >5). These patients were randomly allocated to either a dental appliance or UPPP treatment group. Seven patients withdrew after randomisation but before treatment, leaving 88 patients eligible for the study. The patients were examined using somnography and administered the Minor Symptoms Evaluation-Profile (MSE-P), a QOL questionnaire, before and 1 year after intervention. Thirty-seven patients in the dental appliance group and 43 in the UPPP group completed the 1-year follow-up. The mean values for the three dimensions vitality, contentment and sleep improved significantly 1 year after intervention in the dental appliance and UPPP groups. No difference in the QOL scores at baseline was noted between the groups. One year after intervention, the UPPP group showed significantly more contentment than the dental appliance group. In contrast, vitality and sleep dimensions did not differ between the two treatment groups. No significant correlations were observed between the QOL scores and somnographic values. In conclusion, quality of life improved significantly in the dental appliance and UPPP groups 1 year after intervention. However, the dental appliance group showed a lower level of contentment than the UPPP group possibly due to the continuation of the dental appliance, even though the somnographic values were superior in the former group.

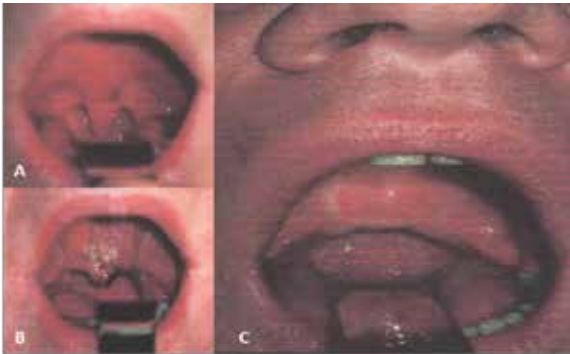A recent Meta-analysis review of LAUP suggested that the procedure should not be used for the treatment of patients with any significant OSAHS (Verse et al., 2000). Battagel et al., (1996) supported minimalist LAUP for those patients who snore loudly with no symptoms of OSAHS.

It is important to differentiate, when using UPPP or related surgical operations, between those patients who are 'simple snorers' and those who exhibit clinical OSAHS. The operation is widely used on the former group and it is suggested that a sleep study assessment to exclude OSAHS is undertaken, given that there is considerable evidence that UPPP has an adverse effect on the patient's subsequent ability to use nCPAP, should they subsequently develop OSAHS (Mortimer et al., 1996; Janson et al., 2000).

However, the operation is not without side effects. A part from significant pain, immediate post-operative inability to seal the nasal from the oral cavity is common. Long-term fistulae, palatal stenosis, and alterations in voice have also been reported (Riley et al., 1987 and 1990a).

More-over, the operation is not always successful (Riley et al., 1987 and 1990b) as any obstruction may be present at more than one site or occur lower down in the airway, thus will be unaffected by (UPPP).

Where the subjects are loud snorers, however, this symptom usually improves. For this reason, palatal surgery, now offered as a minimal laser procedure, may be of benefit to subjects who snore, but only after a diagnosis of OSAHS has been excluded (MacDougland I, 1994; Battagel et al., 1996).



**Figure 2. Uvulo-palato-pharyngoplasty**

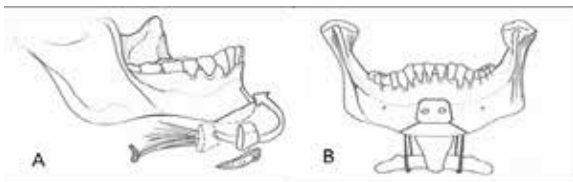
Pre-operative photo shows an enlarged soft palate and midline uvula can be noted.

Post-operative photo shows shortened soft palate together with the Laser created 'battens' in the soft palate.

Three month after surgery shows the healed soft palate with the three battens visible as white lines within the soft palate. Taken from snoring.com.au

Mandibular retrognathia has been linked with OSAHS. The link is explained by the resulting repositioning of the tongue and consequential obstruction of the pharyngeal space. During the 1980's, the recognition of the importance of the tongue position led to the application of orthognathic surgical procedures for the management of OSAHS. The procedures involved may range from simple genirotuberle advancement to the more complex bimaxillary advancement with or without genioplasty and the hyoid suspension. The report of maxillofacial surgery appears good, with 97% control of sleep apnoea despite some surgical mandibular relapse (Riley et al., 1987 and 1990a).

The **geniotuberle advancement** or 'geniotomy' as it is sometimes known was a surgical approach developed by Riley et al., (1987). The procedure is designed to advance the tongue without having any significant effects upon lower facial aesthetics, and is particularly useful in cases where mandibular dimensions are 'normal'. The surgery involves sectioning a central block of bone beneath the lower incisors (including the genial tubercle), and advancing the segment anteriorly. As a consequence of the advancement of the attachments for the genioglossus and the geniohyoid muscles both the tongue and the hyoid bone are likewise advanced.



Diagrammatic representation of the anterior movement of the freed segment of mandible with the attached genioglossus to its new position anterior to the mandible.

The freed segment of mandible is fixed in position anterior to the mandible. The hyoid is freed from its inferior attachments in the neck and is suspended from the anterior mandible by strips of fascia lata.

(Taken from Sher AE et al., The Efficacy of surgical modi-

fications of the upper airway in adults with OSAHS. Sleep 1996; 19: 156-177).

Adjunctive procedures such as **hyoid bone suspension** using facial lata harvested from the thigh are sometimes employed to advance the hyoid bone, opening up the hypopharyngeal region via its attachments to the epiglottis, vallecula and tongue base. Unfortunately, hyoid suspension as an isolated procedure has failed to demonstrate any real benefit and is therefore often undertaken only in conjunction with genirotuberle advancement (Riley et al., 1990a).

When the chin is deficient, a standard **advancement genioplasty** has proven to be quite useful in the treatment of OSAHS. Besides the obvious aesthetic advantages, the procedure also brings forward anterior digastric muscle attachments, effectively providing forward traction to the hyoid bone and consequential tendency to open up the hypopharynx.

In those cases with a cephalometrically measured retrognathic mandible, it is possible to use a mandibular repositioning appliance as a diagnostic aid, in order to establish the efficacy of moving the mandible forward before undertaking actual surgery (McDonald JP, 2003).

Riley R and Powell NB (1990b) found that 65% of patients under their care improved with **mandibular forward osteotomy surgery**. Lowe AA, (1993) agreed that the procedure was beneficial but only where the obstruction was in the hypopharynx. Yu L et al., (1994), however, found mandibular advancement to be an unpredictable procedure.

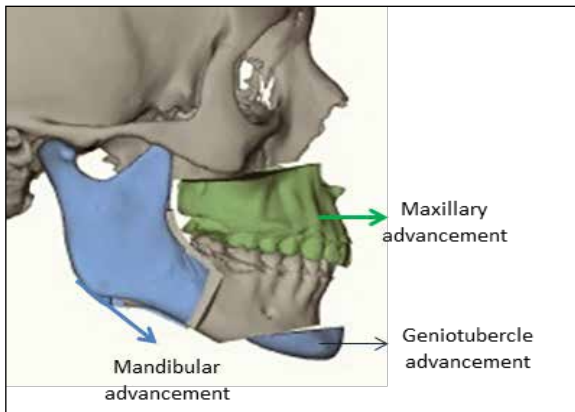
The only disadvantage to this approach, is the prolonged period of pre-surgical orthodontic treatment often necessary to decompensate the dental arches so that a functional long - term occlusion may be attained.

Although traditionally **bimaxillary advancement surgery** was originally reserved only for those OSAHS subjects with 'major' skeletal base discrepancy, the simultaneous advancement of the maxilla (Le Fort I down fracture osteotomy), and of the mandible (bilateral sagittal split osteotomy), is becoming more popular approach for OSAHS subjects who have failed to accommodate or respond to other more conservative treatment modalities. In fact, Riley et al., (1990a) have demonstrated that the bimaxillary advancement procedure is the most successful surgical procedure so far developed for the management of OSAHS. They reported good success rate, with 97% control of the sleep apnoea despite some postoperative surgical mandibular relapse. Furthermore, advancement genioplasty or geniotuberle advancement may also further augment the pharyngeal space when undertaken together with the bimaxillary advancement surgery. Where both jaws are advanced by the same amount, no pre-surgical orthodontic procedures are normally required. Waite PD (1998) and Krekmanov et al., (1998) suggested that the maxillary / mandibular advancement using Le Fort I and surgical splint mandibular osteotomies, permitted greater forward movement of the mandible whilst preserving the occlusion. Postoperative success has proved to be stable over a two-year period (Conradt et al., 1997).

In cases where unequal jaw surgery advancement is necessary, orthodontic is essential to prepare the occlusion prior to surgery, to ensure that profile changes are minimised and that the post surgical occlusion is acceptable (Battagel

et al., 1996).

On the evidence available, therefore, maxillary / mandibular advancement remains largely untested (McDonald JP, 2003).



**Figure 4. Maxillo-mandibular advancement**

OSAHS may also be diagnosed in children, which may frequently be associated with tonsillar and adenoid hypertrophy. Such patients are recommended by Linder-Aronson (1970, 1979), for **tonsillectomy and / or adenoidectomy procedures** to 'cure' sleep apnoea, snoring, daytime sleepiness, mouth breathing and abnormal facial growth. Affected children tend to be shorter in stature than their peers (Battagel et al., 1996). It has been suggested that hypertrophic tonsils alone does not give rise to OSAHS (Battagel et al., 1996).

Djupesland et al., (1992); Miljeteig H and Tvinnereim M., (1992) described an operation termed uvulo-palato-pharyngo-glossoplasty (UPPGP) which incorporated a modified UPPP with limited resection of the tongue base. Fujita S et al., (1990, 1991) and Woodson et al., (1992) under took midline glossectomy and liguloplast to create an enlarged retrolingual airway.

Chabolle F et al., (1999) combined tongue base reduction with hyo-epiglossoplasty in a small study of 10 patients and reported considerable improvement.

Tongue reduction procedures have not been popular because of its complications. Most are done only after a tracheostomy is undertaken due to the associated oedema. **Tongue reduction surgery** is reserved for unusual cases of OSAHS, such as acromegaly or marked macroglossia as in trisomy-21 children.

Weight loss is an effective treatment for OSAHS, so it would follow that **bariatric surgery** would be efficacious (Harman et al., 1982; Smith et al., 1985; Surat et al., 1986). Mayer et al., (1996) noted the relationship between BMI, age and upper airway measurements in snorers and sleep apnoea patients. Restrictive operations like gastric sleeve surgery make the stomach smaller and help people lose weight. With a smaller stomach, he / she will feel full a lot quicker than they were used to. Many techniques are available: Bypass, sleeve and banding gastric surgeries.

Charuzi et al., (1992) reported on a case series of 47 morbidly obese subjects followed-up after one year and again after seven years following surgery. They reported a significant decrease in the number of apnoeic episodes per hour

of sleep, due primarily to the weight loss. It was noted that those individuals who subsequently gained weight began to increase the frequency of apnoeic episodes.

Sugarman et al., (1992) reported on 126 patients treated by bariatric surgery over a 10-year-period. Of the 40 patients with pre- and post- weight reduction sleep polysomnograms, the sleep apnoea index fell from  $64 \pm 39$  to  $26 \pm 26$  ( $P < 0.0001$ ), and was associated with significant improvement in other measurable sleep indices.

Dhabuwala et al., (2000) noted an improvement in co-morbidly factors following weight loss from gastric bypass surgery.

There is, however, as yet no controlled trial available on the efficacy of bariatric surgery in inducing weight loss and improvement in clinical outcome (McDonald JP, 2003).

### SURGICAL COMPLICATIONS

Despite the apparent success rates of some surgical technique used to manage OSAHS, there are also significant drawbacks. These include pre-operative, intra-operative and immediate post-operative complications such as haemorrhage, infection, airway obstruction and anaesthetic complications. Other suggested problems include the distortion of the abnormal loading of the temporomandibular joints, prolonged intermaxillary fixation, a negative aesthetic impact, temporary or indeed permanent anaesthesia, instability of the skeletal advancement and perhaps most importantly, the inability to provide an accurate long-term prognosis due to a lack of adequate data. It must be stressed that OSAHS patients frequently present with other medical problems, which unlike routine orthognathic cases, may necessitate careful preoperative medical assessment and treatment and of course special anaesthetic care.

### Conclusion

All patients with suspected sleep apnoea / hypopnoea syndrome and their partners should complete an Epworth questionnaire to assess the degree of pre-treatment sleepiness (Johns et al., 1991). If OSAHS is suspected, then polysomnography should be undertaken to confirm the diagnosis. Weight loss without resort to bariatric surgery should be encouraged where it is contributing to OSAHS. CPAP therapy is the first choice therapy for moderate to severe patients; intra-oral devices are adjunct therapy for snorers and mild to moderate OSAHS sufferers. Use of UPPP or LAUP for the treatment of OSAHS, as opposed to simple snoring is not recommended (SIGN, 2003), because palatal surgery can compromise later CPAP use if patients develop OSAHS.

## REFERENCE

1. Guyette RF, Waite PD. Adjunctive surgical procedures in obstructive sleep apnoea. *Oral and Maxillofacial Surgical Clinics of North America* 1995; 7: 301-310.
2. Kim SH, Eisele D, Smith PL, Schneider H, Schwartz A. An evaluation of patients with sleep apnoea after tracheostomy. *Arch Otolaryngol Head Neck Surg* 1998; 124: 996-1000.
3. Conway WA, Victor LD, Magilligan DJ, Fujita S, Zorick FJ, Doth T. Adverse effects of tracheostomy for sleep apnoea. *J Am Med Assoc* 1981; 246: 347-350.
4. Meyer JB, Knudson RC. The sleep apnoea syndrome. Part II: Treatment. *The Journal of Prosthetic Dentistry* 1990; 63: 320-332.
5. SIGN (Scottish Intercollegiate Guidelines Network). Clinical guideline no 73. Edinburgh: The Network; 2003. Jun, Management of obstructive sleep apnoea/hypopnoea syndrome in adults: a national clinical guideline [Internet] [cited 2009 Apr 16]. Available from: <http://www.sign.ac.uk/pdf/sign73.pdf>.
6. Olsen KD, Kern EB. Nasal influence on snoring and obstructive sleep apnoea. *Mayo Clin Proc* 1990; 65: 1095-1105.
7. Kuna ST, Sant' Ambrogio G. Pathophysiology of upper airway closure during sleep. *J Am Med Assoc* 1991; 266: 1384-1389.
8. Freidmann M, Tanyeri H, Lim JW, Landsperg R, Vaidyanathan K, Caldarelli D. Effect of improved nasal breathing on obstructive sleep apnoea. *Otolaryngol Head and Neck Surg* 2000; 122: 71-74.
9. McDonald JP. A review of surgical treatment for obstructive sleep apnoea/hypopnoea syndrome. *Surgeon*. 2003 Oct; 1(5): 259-264.
10. Kamami YV. Outpatient treatment of snoring with CO2 laser: Laser assisted UPPP. *Otolaryngol* 1994; 23: 391-394.
11. Ikematsu t. Study of snoring 4th report. Therapy: *J Jpn Oto Rhinol Laryngol* 1964; 64: 434-435.
12. Fujita S, Conway W, Zorick F, Roth T. Surgical correction of anatomic abnormalities in obstructive sleep apnea syndrome: uvulopalatopharyngoplasty. *Otolaryngol Head Neck Surg* 1981 Nov-Dec; 89(6): 923-934.
13. Riley RW, Powell NB, Guilleminault C. Current surgical concepts for treating obstructive sleep apnoea syndrome. *J of Oral and Maxillofacial surgery* 1987; 45: 149-157.
14. Sher AE. Update in upper airway surgery for obstructive sleep apnoea. *Curr Opin Pulm Med* 1995; 1: 504-511. Review.
15. Millman RP, Carlisle CC, Rosenberg C, Kahn D, McRae R, Kramer NR. Simple predictors of uvulopalatopharyngoplasty outcome in the treatment of obstructive sleep apnea. *Chest*. 2000 Oct; 118(4): 1025-1030.
16. Walker-Engstrom ML, Tegelberg A, Wilhelmsson B, Ringqvist I. 4-year follow-up of treatment with dental appliance or uvulo-palato-pharyngoplasty in patients with obstructive sleep apnoea: a randomized study. *Chest* 2002; 121: 739-746.
17. Verse T, Pirsig W. Meta-analysis of laser assisted uvulopalatopharyngoplasty. What is clinically relevant up to now? *Laryngorhinootologie* 2000; 79: 273-284.
18. Battagel JM. Obstructive Sleep Apnoea: Facts Not Fiction. *British Journal of Orthodontics* 1996; 23: 345-324.
19. Mortimer IL, Bradley PA, Murray JA, Douglas NJ. UPPP may compromise nasal CPAP therapy in sleep apnoea syndrome. *Am J Respir Care Med* 1996; 154: 1759-1762.
20. Janson C, Noges E, Svedberg-Randts, Lindberg E. What characterizes patients who are unable to tolerate CPAP treatment? *Resp Med* 2000; 94: 145-149.
21. Riley RW, Powell NB, Guilleminault C. Maxillary, mandibular and hyoid advancement for treatment of obstructive sleep apnoea. *J Oral Maxillofacial Surg* 1990a; 48: 20-26.
22. Macdougland I. Sleep apnoea. *Laser therapy for OSA*. *Nursing Times* 1994; 90: 32-34.
23. Riley RW, Powell NB, Guilleminault C. Maxillofacial surgery and nasal CPAP. A comparison of treatment for obstructive sleep apnoea syndrome. *Chest* 1990b; 98: 1421-1425.
24. Lowe AA. How does the airway lend itself to therapy? Can we predict the success of dental appliances for the treatment of obstructive sleep apnoea based on anatomic considerations? *Sleep* 1993; 16: S93-95.
25. Yu LF, Pogrel MA, Ajayi M. Pharyngeal airway changes associated with mandibular advancement. *J Oral and Maxillofac Surg* 1994; 52: 40-43.
26. Waite PD. Obstructive sleep apnoea: a review of the pathophysiology and surgical management. *J Oral Surgery* 1998; 85: 352-261.
27. Krekmanov L, Andersson L, Ringquist et al. Anterior-inferior mandibular osteotomy in treatment of obstructive sleep apnoea syndrome. *Int J Adult Orthod Orthognathic Surg* 1998; 13: 289-298.
28. Conradt R, Hochban W, Brandenburg U, Heitmann J, Peter JH. Long term follow-up after surgical treatment of obstructive sleep apnoea by maxillo-mandibular advancement. *Eur Respir J* 1997; 10: 123-128.
29. Linder-Aronson S. Adenoids: their effect on mode of breathing and nasal airflow and their relationship to characteristics of the facial skeleton and the dentition. *Acta Otolaryngologica* 1970; S 265: 1-132.
30. Linder-Aronson S. Cephalometric radiographs as a means of evaluating the capacity of the nasal and nasopharyngeal airway. *Am J Orthod Dentofacial Orthop* 1979; 76: 479-490.
31. Djupesland G, Sxhrader H, Lyberg T, Refsum H, Lileas F, Godtlieksen OB. Palatopharyngoglossoplasty in the treatment of patients with obstructive sleep apnoea. *Acta Otolaryngol* 1992; 492: 50-54.
32. Miljeteig H, Tvinnerem M. Uvulopalatopharyngoglossoplasty in the treatment of obstructive sleep apnoea syndrome. *Acta Otolaryngol* 1992; 492: 86-89.
33. Fujita S. Surgical treatment of obstructive sleep apnoea: UPPP and lingoplasty (laser midline glossectomy). In *Obstructive sleep apnoea syndrome: clinical research and treatment* (Guilleminault and Pentinez) 1990; 129-151 Paven Press, New York.
34. Fujita S. Midline laser glossectomy with linguoplasty: a treatment of sleep apnoea syndrome. *Oto Laryngol* 1991; 2: 127-131.
35. Woodson BT, Fujita S. Clinical experience with linguoplasty as part of the treatment of severe sleep apnoea. *Otolaryngol Head / Neck Surgery* 1992; 107: 40-48.
36. Chabolle F, Wagner I, Blumen M, Sequert C, Fleury BDe Dieuleveult T. Tongue base reduction with hyoepiglossoplasty. A treatment of severe obstructive sleep apnoea. *The Laryngoscope* 1999; 109: 1273-1280.
37. Harman EM, Wynne JW, Block AJ. The effect of weight loss on sleep-disordered breathing and oxygen desaturation in morbidly obese men. *Chest* 1982; 82: 291-294.
38. Smith PL, Gold AR, Meyers DA, Haponik EF, Bleeker ER. Weight loss in mildly to moderate obese patients with obstructive sleep apnoea. *Am Intern Med* 1985; 103: 850-855.
39. Suratt PM, Turner BL, Wilhoit SC. Effect of intranasal obstruction on breathing during sleep. *Chest* 1986; 90: 324-329.
40. Mayer P, Pepin JL, Bettaga G. Relationship between BMI, Age and upper airway measurements in snorers and sleep apnoea patients. *Eur Respir J* 1996; 9: 180-189.
41. Charuzi I, Lavie P, Peiser J, Peled R. Bariatric surgery in morbidly obese sleep apnoea patients: short and long term follow-up. *Am J Clin Nutr* 1992; 55: 594-596.
42. Sugarman HJ, Fairman RP, Baron PL, Kiventus JA. Long term effects of gastric surgery for treating respiratory insufficiency of obesity. *Am J Clin Nutr* 1992; 55: 597-601.
43. Dhabuwala A, Cannon RJ, Stubbs RS. Improvement in co-morbidities following weight loss from gastric bypass surgery. *Obes Surg* 2000; 10: 428-835.